Neuromas and Their Management

What is neuroma ?

- Neuros – nerve, oma – tumor
- Represent a physiological response after nerve injury
- All severed nerves will form neuroma
- Only neuromas containing sensory fibers become painful

Definition

" Neuromas are the inevitable, unavoidable, and biologic response of the proximal stump after it has been divided in situations in which regenerating axons are impeded from reentering the distal stump."

Green's Operative Hand Surgery, 6th edition, 2010

Neuroma

- Frequent cause of major disability of the hand
- May impair the function of the whole upper extremity
- Up to 20% to 30% of cases experience debilitating symptoms

Nelson, 1977

- Management is challenging

Historical Review

1634 - Ambrose Pare described a painful amputation neuroma

1811- Odier identified the lesion as a sensitive nodule at the distal end of a transected nerve.

1828- Wood first named the neuroma and described its detailed anatomy.

1874- Virchow and Mitchell first reported a case of neuroma occurring after injury to the median nerve

Anatomy

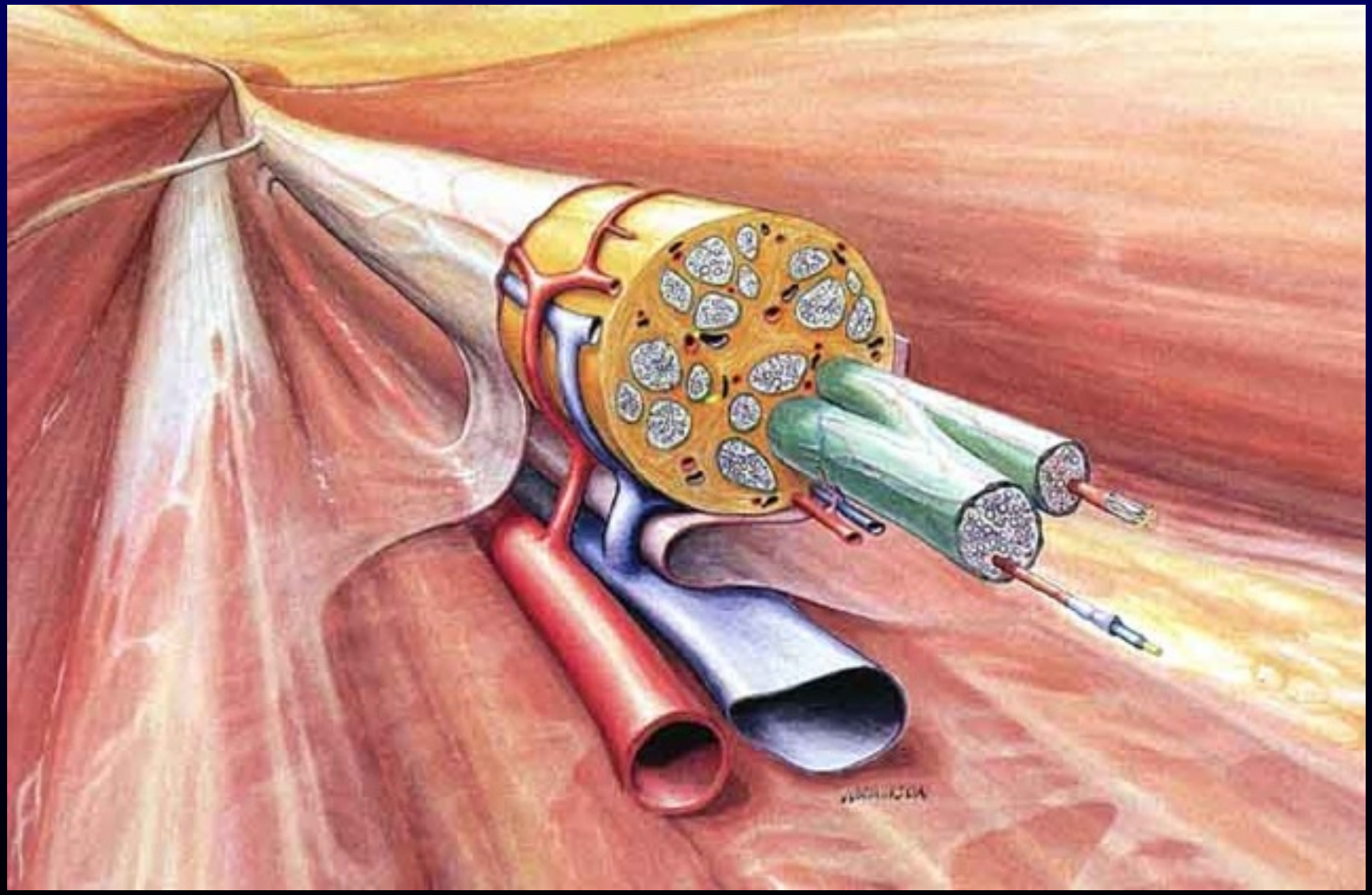

Neuron

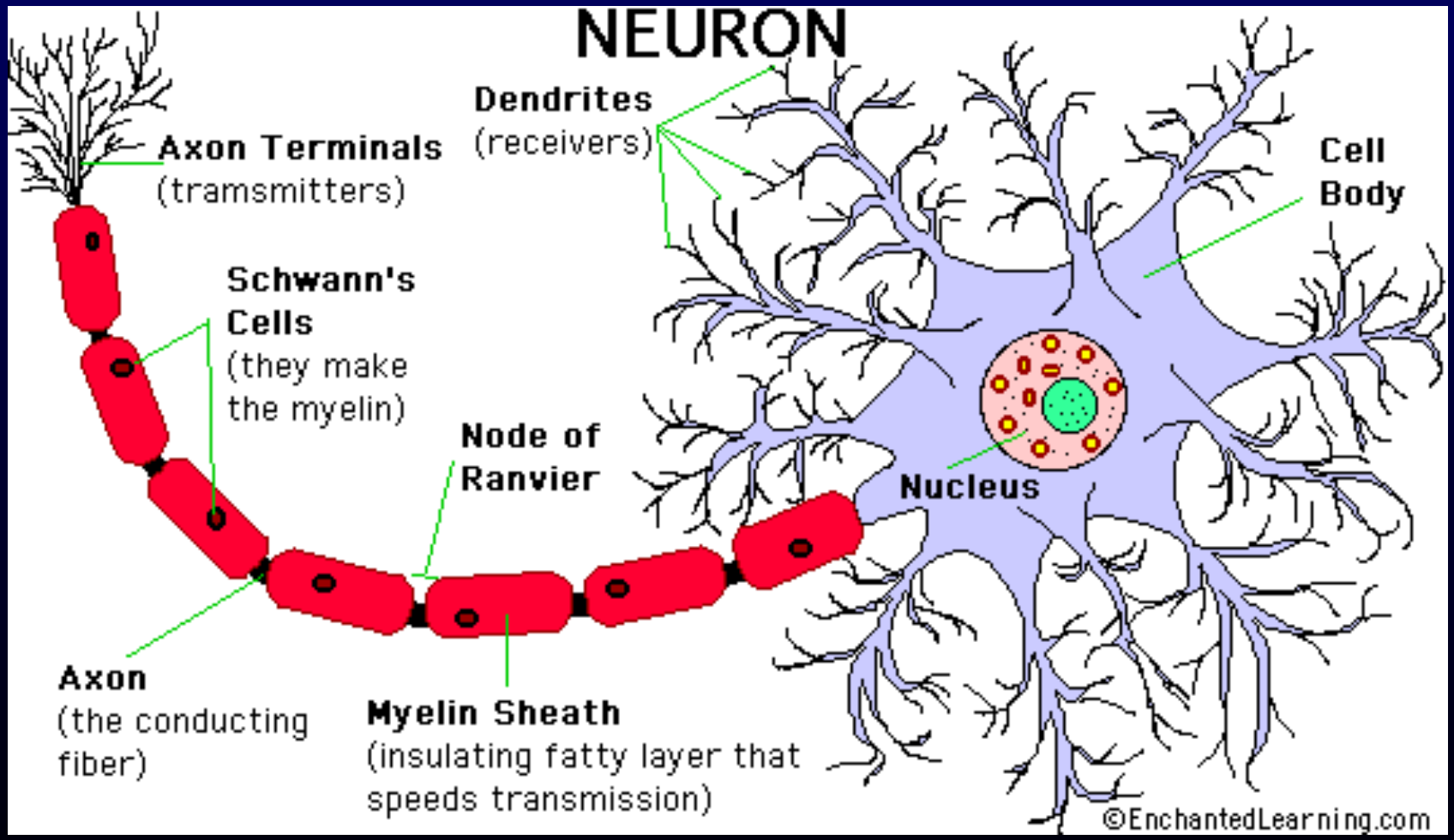
NEURON
Dendrites
(receivers)
Axon Terminals
(tramsmitters)
Cell
Body
Schwann's
Cells
(they make
the myelin)
Node of
Ranvier
Nucleus
Axon
(the conducting
fiber)
Myelin Sheath
(insulating fatty layer that
speeds transmission)
©EnchantedLearning.com

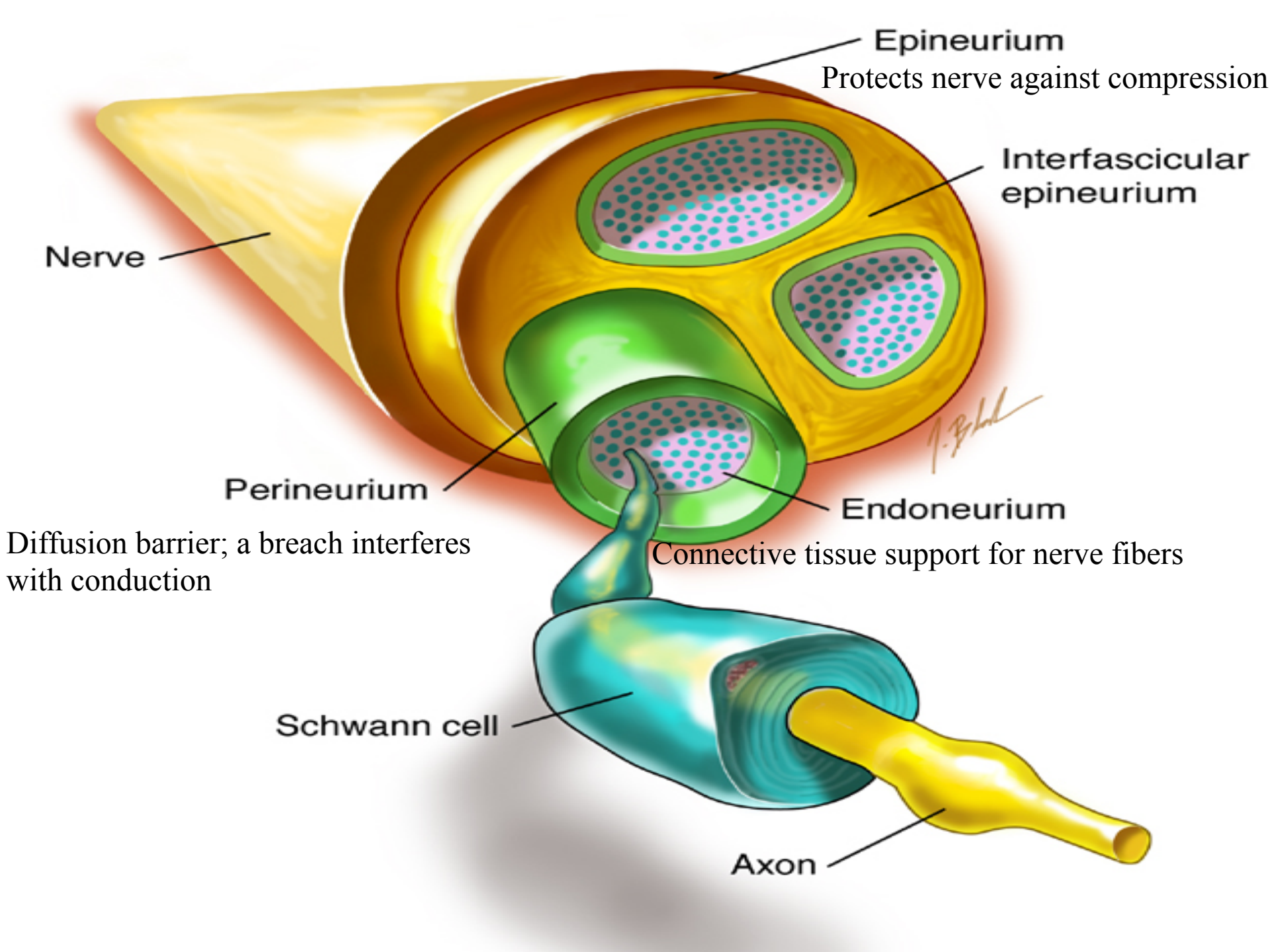
Epineurium
Protects nerve against compression
Interfascicular epineurium
Nerve
Perineurium
Endoneurium
Diffusion barrier; a breach interferes with conduction
Connective tissue support for nerve fibers
Schwann cell
Axon

EPINEURIUM

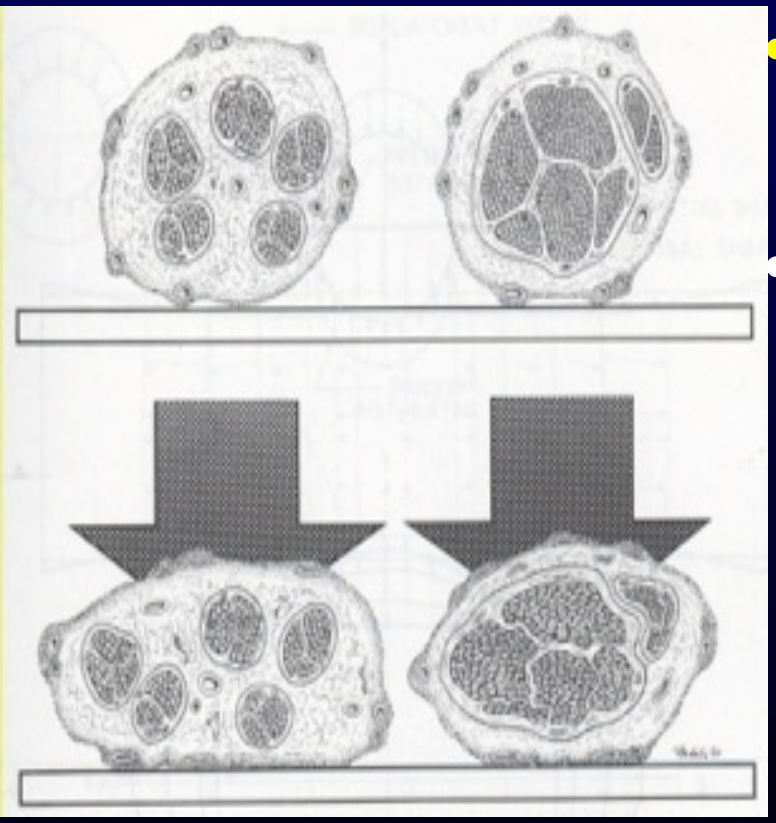

- Tough fibrous sheath that surrounds the nerve
- Protects fascicles- cushioning effect

PERINEURIUM

- Connective tissue wrapping surrounding a nerve fascicle
- Outer and inner basement membrane
- Collagen and elastic fibers
- Mechanically very strong(350-750 mm Hg before rupturing)

Endoneurium

- Layer of delicate connective tissue surrounding the axon

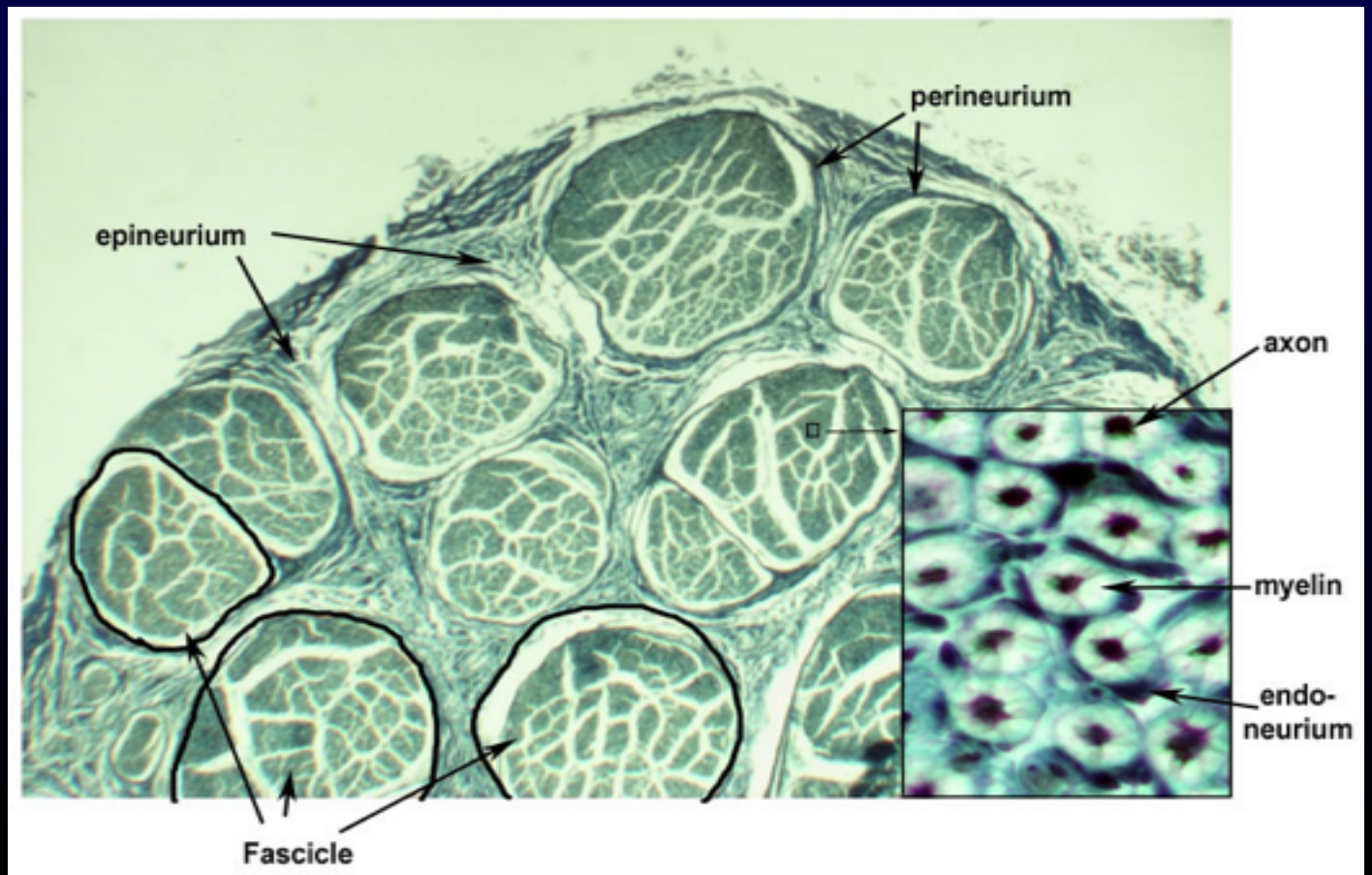

Nerve fiber classification

A delta, A gamma, A alpha, A beta, B, C

- **A delta—skin temperature and pain—ncv = 15 ms**
- **A gamma—motor efferent to spindle—ncv = 20 ms**
- **A alpha spindle afferents, motor efferents—ncv = 100ms**
- **A beta—skin touch and pressure afferents—ncv = 50 ms**
- **B --sympathetic preganglionic—ncv = 7 ms**
- **C –skin pain, sympathetic postganglionic—ncv = 1 ms**

Pathophysiology

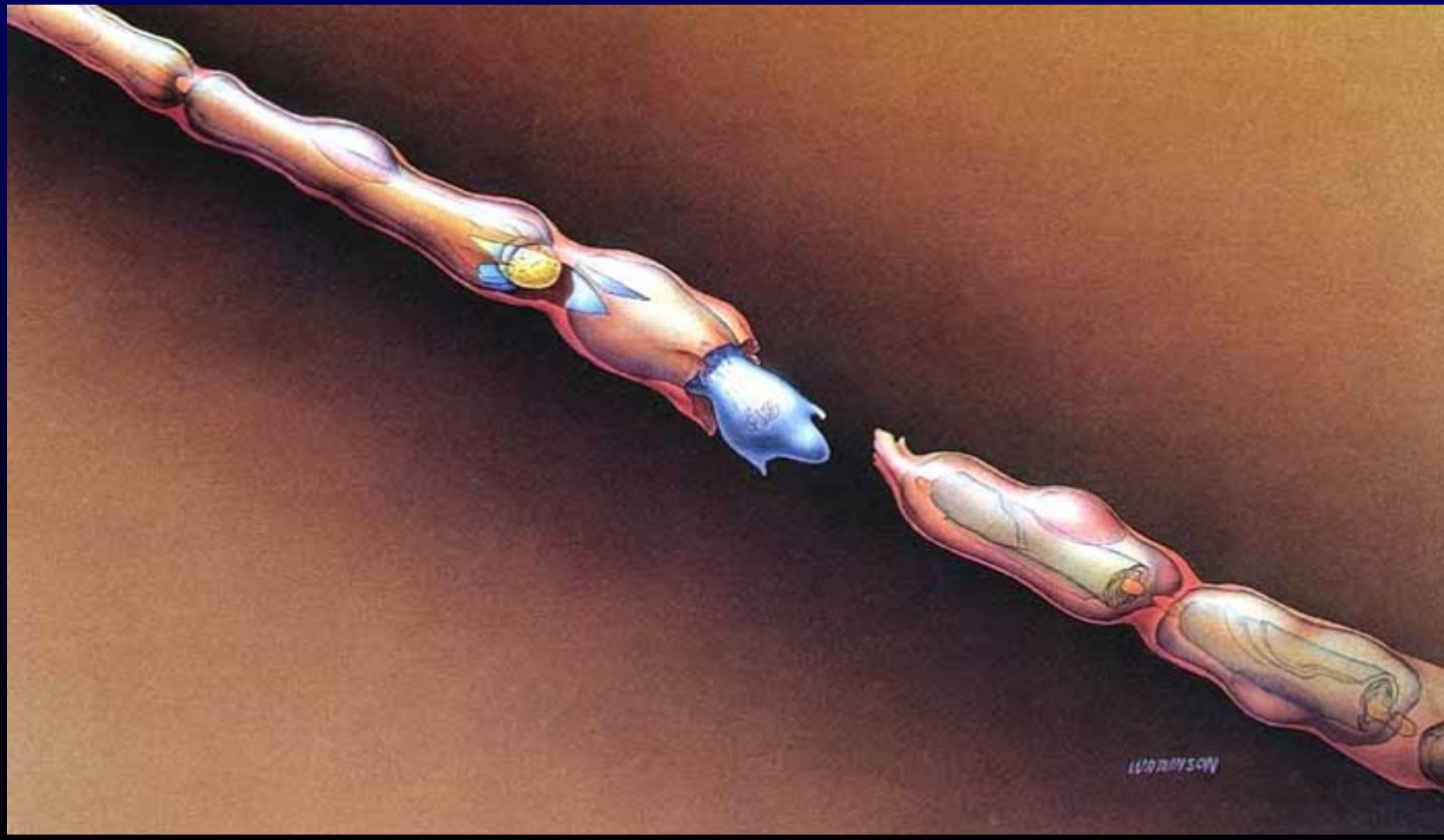

Injury

- Traumatic nerve injury:
  - Degeneration of the proximal stump for a variable distance
  - Wallerian degeneration of the distal stump
  - Retrograde signals to cell body stimulate regeneration of axons and antegrade transport and synthesis of peptides
  - Upregulation of neurotrophins, neural cell adhesion molecules, and cytokines

Cont…

- Satisfactory alignmnent of motor and sensory fascicles
  - Functional recovery
- Abnormal regeneration fascicles
  - Functional deficit
  - Hyperalgesia in area of nerve distribution
  - Painful neuromas

Why pain?

- Normal nociception results from stimulation of A-delta and C fibers

  Meyer et al, 1985

- With neuromas, possible abnormal communication between A-beta fibers and nocicieptive fibers
- Overall sensentization and hypersensibility of the fibers=> hyperexcitable, hyperalgesic state

Why pain?

1. Persistent mechanical or chemical irritation of the axons within the neuroma
2. Development of spontaneous and disturbing sensory symptoms
   - From persistent stimulation of the axons within the neuroma
   - Accompanied by development of spontaneous activity of neurons within the dorsal root ganglion, dorsal horn of the spinal cord, and at even more proximal levels in the CNS

Watson J, et al. Neuromas of the Hand and Upper Extremity. *J Hand Surg*. 2010; 35A:499-510

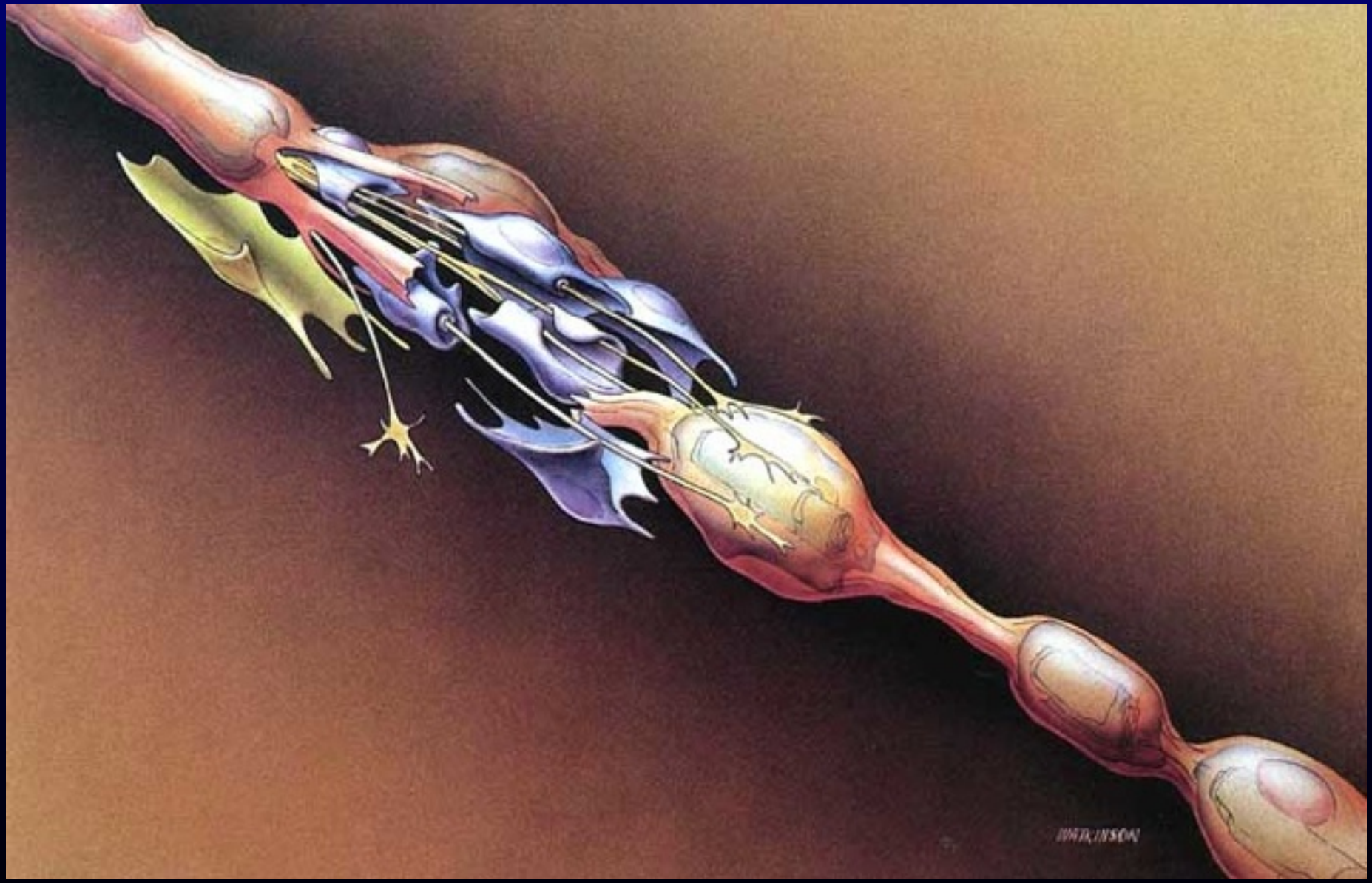
HUTCHISON

Size of neuroma

- Larger when
  - Closer to the cell body
  - Nerve with more connective tissue
  - Nerve with widely spaced fascicles
  - Associated soft tissue injury
  - Infection
  - Repeated irritation, pressure, friction, repeated trauma
  - Presence of foreign body
- Does not correlate with the amount of pain
- Is not influence by blood supply

Petropoulos and Stefanko, J Surg Res1961

Classification (Sunderland 1978)

- **Neuroma-in-continuity**
  1. Spindle neuroma
  2. Lateral neuroma
  3. Neuroma after nerve repair
- **Neuromas in completely severed nerves**
- **Amputation stump neuroma**

Neuroma-in-continuity
Spindle Neuroma

- Perineurium intact
- Axonal and endoneural disruption
- After traction injury, chronic irritation, friction or pressure
- Nerve compression syndrome
- Morton's neuroma, bowler's thumb, PIN, meralgia paresthetica

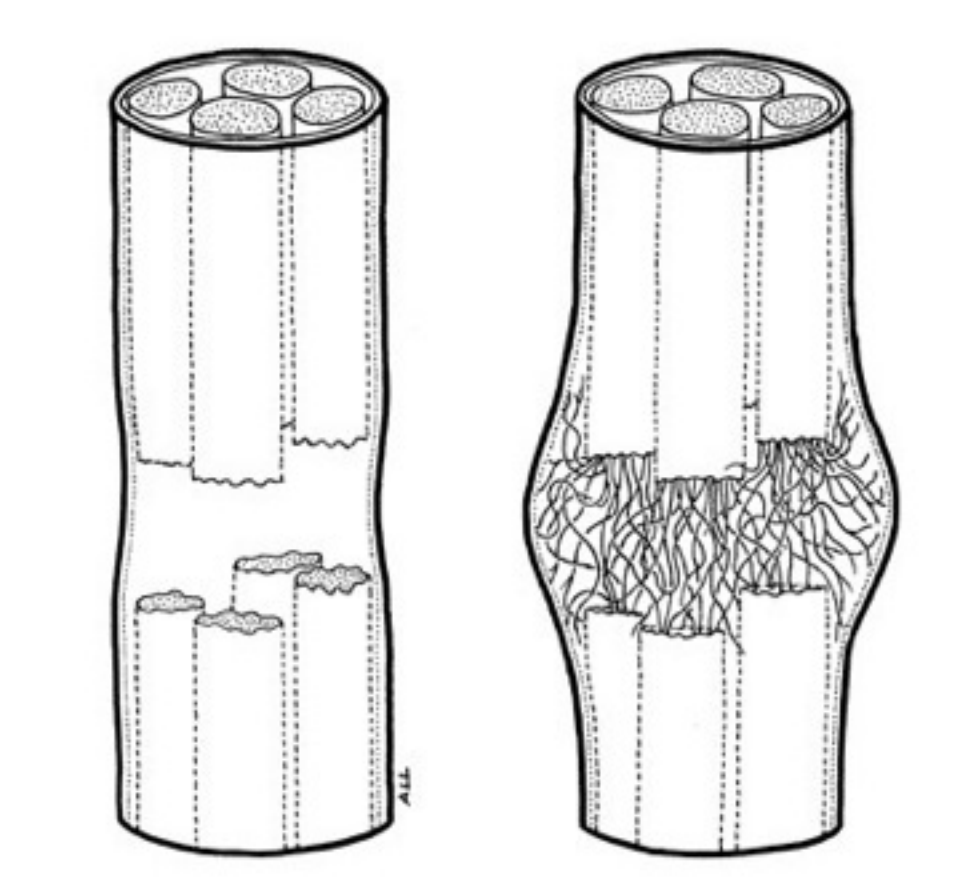

Bowlers thumb

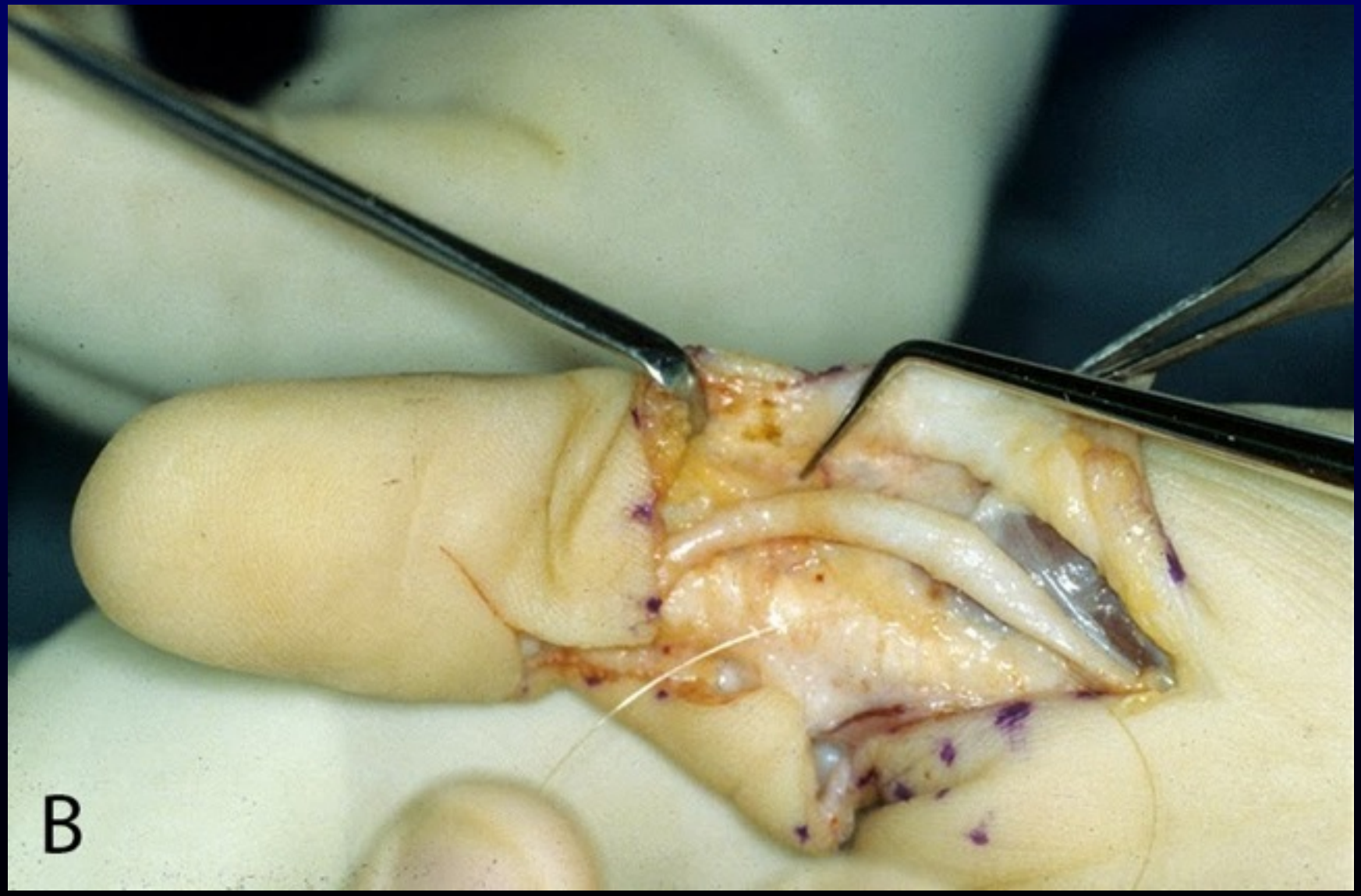

Pseudoneuroma in continuity

Swelling or Enlargement in an intact nerve

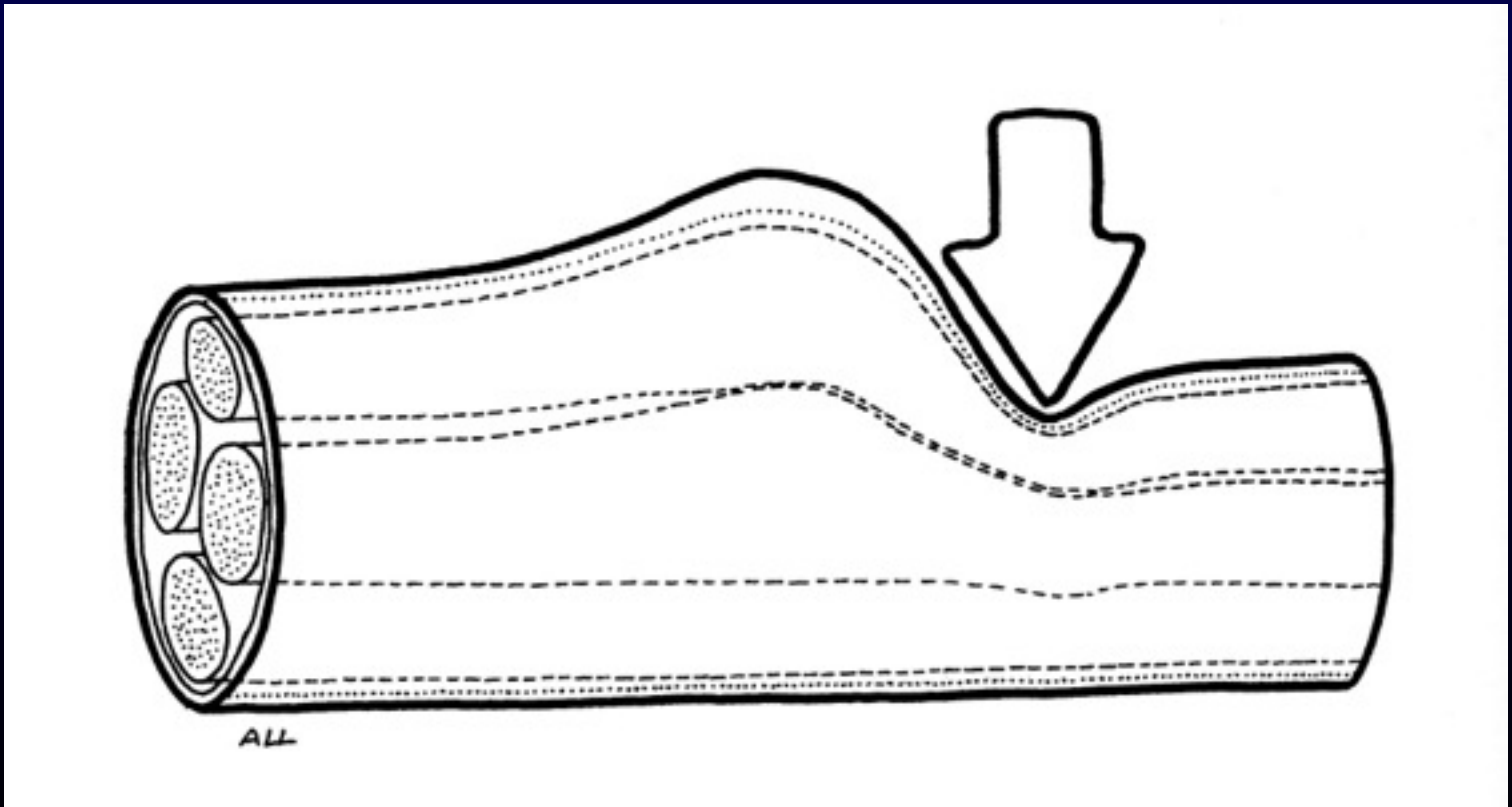

Neuroma-in-continuity
Lateral Neuromas

- Only part of the nerve is disrupted
- Caused by sharp objects
- Produce partial loss of function or sensation and neuromatous pain at the site of injury.
- Size depends on
  - Number of fascicles severed
  - Distance regenerating axons must span

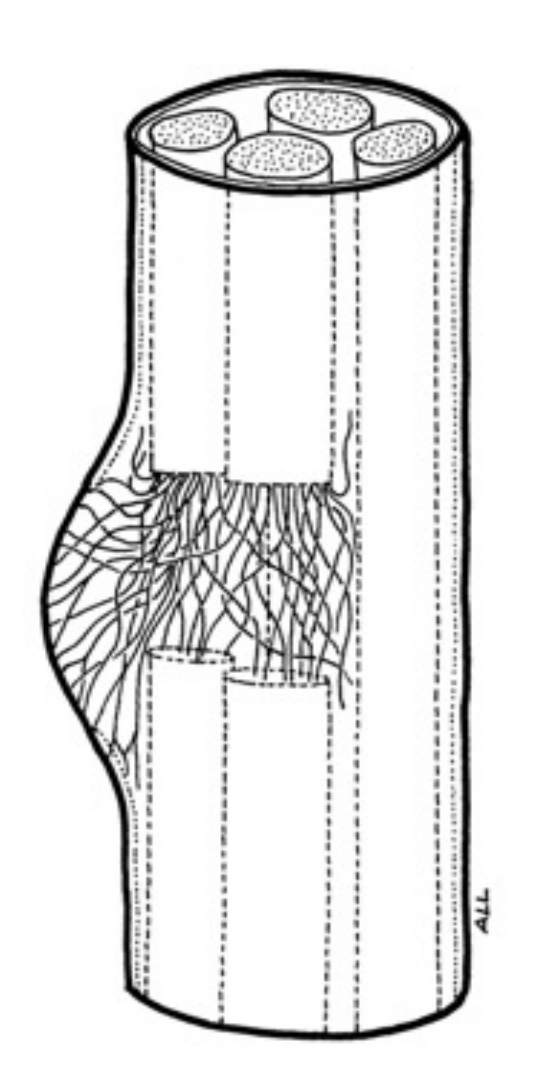

Neuroma-in-continuity
Neuroma after repair

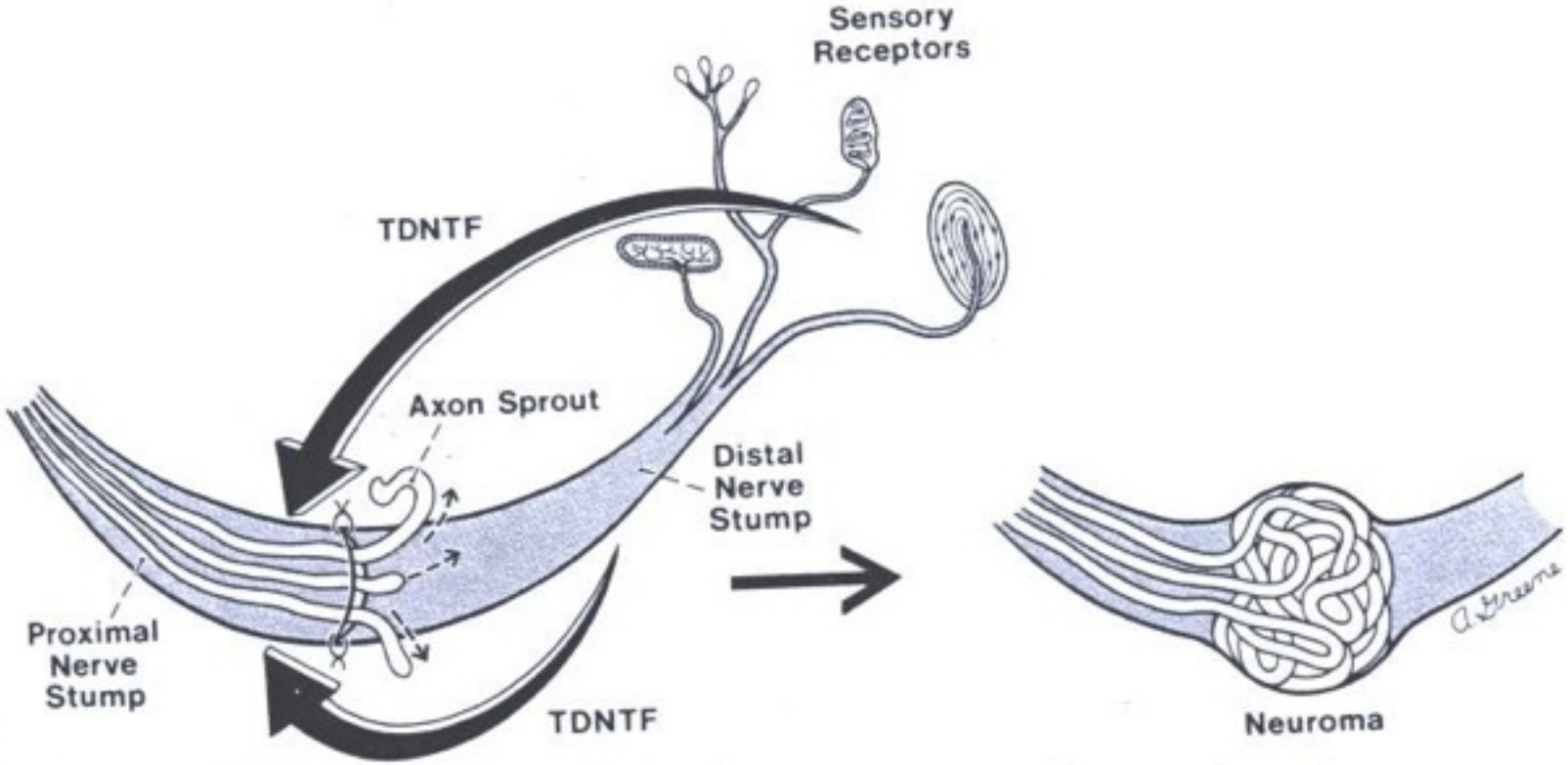

FIG. 2. In the face of an obstruction, such as a suture or poorly approximated nerve stumps, the proximal stump axons, still stimulated by their target, grow in a disorganized, poorly oriented fashion resulting in a neuroma.

Neuromas in completely severed nerves

Terminal neuroma

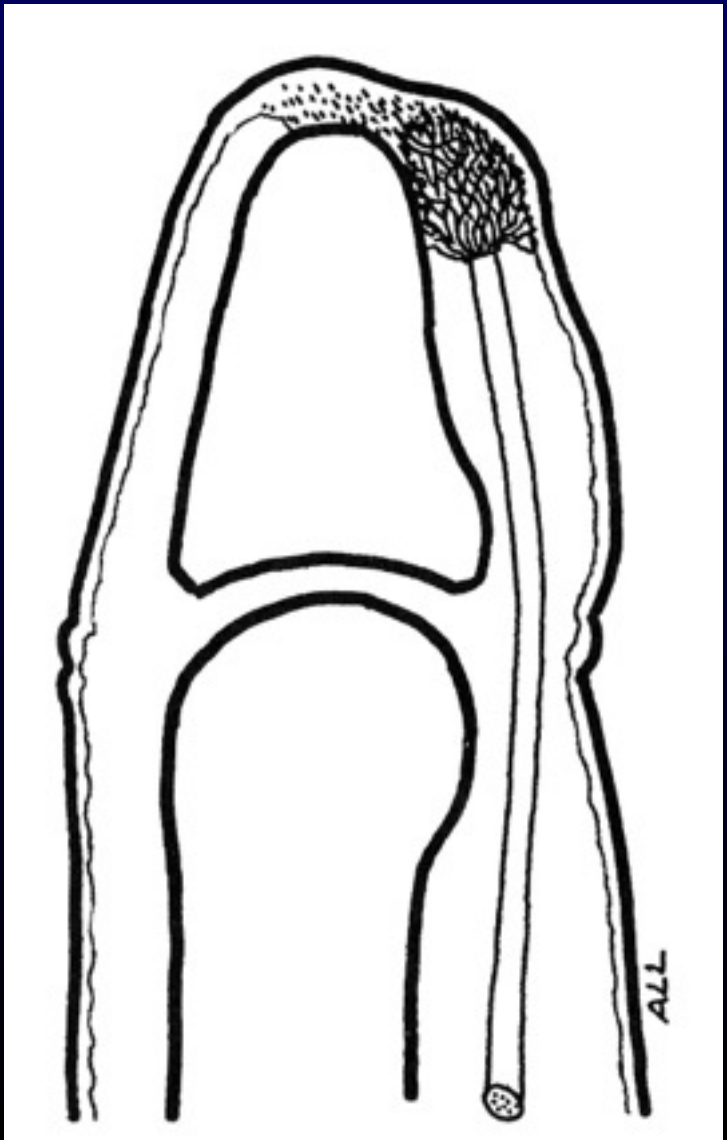

Amputation neuromas

- A form of traumatic neuroma

Diagnosis

- History of nerve injury-trauma
- A painful scar with/without palpable mass
- Altered sensibility in the distribution of the involved nerve
- Pain produced has intense and unpleasant quality
- Electrical sensation radiating to the sensory territory of the injured nerve
- Asymptomatic at rest
- Symptomatic every time mechanical stimuli are applied

Examination

- Percussion and reproduction of pain to the sensory territory of the injured nerve.

Tinel & Hoffmann 1915.

Diagnosis: Investigations

- MRI is useful in finding the exact location of an amputation neuroma

Donnal J.F. 1990

- EMG is useful as an adjunct to determine the level and extent of injury.

Intraoperative Investigation

- Small electrode applied to individual fascicles just proximal and distal to lesion
- Record evoked response and nerve conduction velocity

Management

“Axons have the capacity to regenerate for years.”

Holmes W, Young JZ J Anat 77:63, 1942

“ There is no procedure that is completely and consistently successful in preventing neuroma formation.”

Sunderland 1978

“ More than 150 methods ”

Wood & Mudge, 1987

"Treatment of a painful neuroma is deeply unsatisfactory. The number of operative techniques described is so large that it is clear that not one is wholly reliable"

Rolfe Birch. Green's Operative Hand Surgery 6th ed.

“ Only destruction of a cell body can inhibit axonal regeneration. ”

Guttmann and Medawar J Neurol Psychiatry 1942

Prevention

- Careful repair or grafting.
- Amputation=> cutting the nerve on traction and allowing it to retract into nontraumatic tissues

Nerve Growth Factor Inhibition Prevents Traumatic Neuroma Formation in the Rat

Gil S. Kryger, BS, Zol Kryger, BS, *San Francisco, CA,* Feng Zhang, MD, PhD, *Jackson, MS,* David L. Shelton, PhD, *South San Francisco, CA,* William C. Lineaweaver, MD, *Jackson, MS,* Harry J. Buncke, MD, *San Francisco, CA*

Nerve growth factor (NGF) is thought to play a role in the pathogenesis of neuroma formation as well as in the development of neuropathic pain. In this study we attempted to antagonize NGF by using trkA-IgG, an inhibitor of NGF, consisting of the NGF receptor linked to an immunoglobulin. It was delivered by an implanted osmotic pump directly to the site of a sciatic nerve transection in 16 rats for 30 days. The animals were monitored daily for the first 2 weeks for evidence of auto-cannibalization (autotomy) of the denervated foot (a sign of neuropathic pain). Four (25%) of the 16 rats receiving trkA-IgG exhibited such cannibalization compared with 9 of 15 control rats (60%) that underwent an identical procedure but were not treated with the trkA-IgG solution. One month after surgery the sciatic nerves and representative dorsal root ganglia (DRG) from these rats were evaluated histologically. Six of the 16 experimental rats (38%) demonstrated histological evidence of neuroma formation compared with 12 of the 15 controls (80%). There were no histological differences between the DRG from the two groups. These results support the notion that inhibiting NGF following peripheral nerve injury in the rat can reduce neuroma formation and neuropathic pain without damaging the cell bodies of the transected neurons. (J Hand Surg 2001;26A:635–644.

Key words: Neuroma, neuropathic pain, nerve growth factor, trkA-IgG, rat, sciatic nerve.

Conservative Treatment

- Physical therapy:
  Tapping, massage, ultrasound, TENS, percussion biofeeback, relaxation therapy, acupuncture
- Desensitization
- Medications:
  NSAIDS, Amitriptyline, carbamazepine, neurontin, pregabalin
- Psychotherapy
- If favorable response has not occurred by 6 months, it is not likely to occur

TENS

- Stimulate inhibitory pathways and control pain

  interfering with neural transmission of signals from underlying pain receptors

- 33% improved with TENS alone and 44% showed improvement with other modalities

  Long, Arch Surg, 1977

- Should only be used in the first three months following injury

  Omer, OCNA, 1981

Triamcinolone Injection

- Rationale: Scar softening and flattening
  : Suppress ectopic neural discharge

  Dever et al, Pain, 1986

- Effective in localized digital neuroma

- Less successful for deeper neuroma in palm and wrist

- 34 neuromas, 50% relieved after single injection, 80% after multiple injection

  Smith JR, Gomez NH: JBJS 52A:71-83, 1970

Surgical Treatment

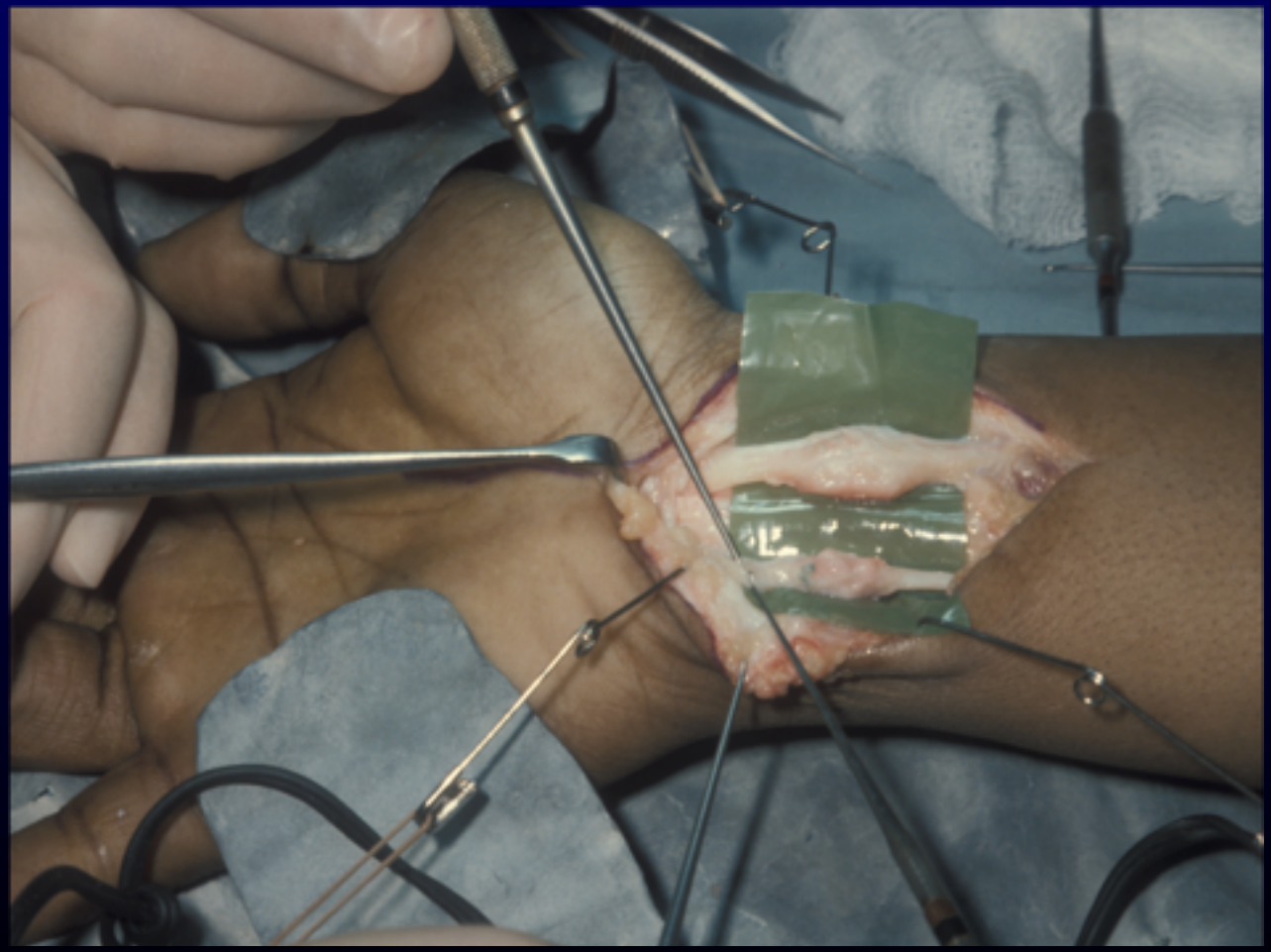

Principles of surgery

- Nerve grafting if appropriate distal nerve and sensory receptors are available

- Innervated free tissue transfer if distal nerve is not available and function of the injured nerve is critical

- Resection of neuroma and transposition if :
  1. *Function of injured nerve is not critical*
  2. *Local tissue environment is not suitable for nerve graft*
  3. *Multiple previous unsuccessful surgeries*

Methods of Treatment

- Methods to block or suppress axon regeneration
- Methods to promote axon dispersal
- Methods to protect the neuroma from mechanical irritation

Methods to block or suppress axon regeneration

- Chemical Agents
- Crushing of proximal nerve stump
- Cauterization
- Nerve ligation
- Epineural sleeve ligation and modified methods
- Capping
- Implantation into nerve: centro-central tech.
- Molecular neurosurgery

Chemical Agents

- **Alcohol: 60-100%,**
- **Osmotic agent**
- **Tannic acid solution: 2-10%**
- **Formaldehyde: 5-40%**
- **Chromic acid**
- **Iodine**
- **Uranium nitrate, mustard**
- **Gentian Violet**
- **Phenol**
- **Phenol-Glycerol**
- **Carbonic acid,**
- **Formalin**
- **Mecuric chloride**
- **Piric acid**
- **Nitrogen**

Chemical Agents

- No real value in preventing the formation of neuroma *Sunderland, 1978*

- 80% alcohol and formaldehyde produced greatest amount of nerve necrosis

Petropoulos and Stefanko, 1961

Experimental Study

- Use of Ricin
- Suicide transport via retrograde transport and central toxicity

Wiley et al, 1982

Suicide Transport: Destruction of Neurons by Retrograde Transport of Ricin, Abrin, and Modeccin

Abstract. *Certain toxic lectins, including ricin, are retrogradely transported along neuronal processes to the cell body where they inactivate ribosomes, resulting in neuronal death. This process of "suicide transport" suggests a powerful new experimental strategy for solving neurobiological problems.*

Physical Methods

- Hot water, heat, cauterization, freezing, electrocoagulation, radioactive substance, CO2 laser
- Unsuccessful in suppressing neuroma formation *Sunderland, 1978*
- Tissue necrosis results in painful neuroma formation

CO2 laser

- No neuroma formation in 12 patients
- No recurrent pain over 2 years

Asher, 1979

Ligation

- Close fascicles by suture and prevent axonal regrowth

- Limiting neuroma formation *Sunderland 1978*
  Chavannaz and Jegorow, 1940

- Unreliable *Chieslak, 1946*
  Herrmann, 1956

Epineural sleeve ligation
(Tupper & Booth, JHS, 1976)

- 45 neuromas in 28 patients
- 81% excellent or satisfactory results as primary procedure
- 87% excellent results if second procedure done

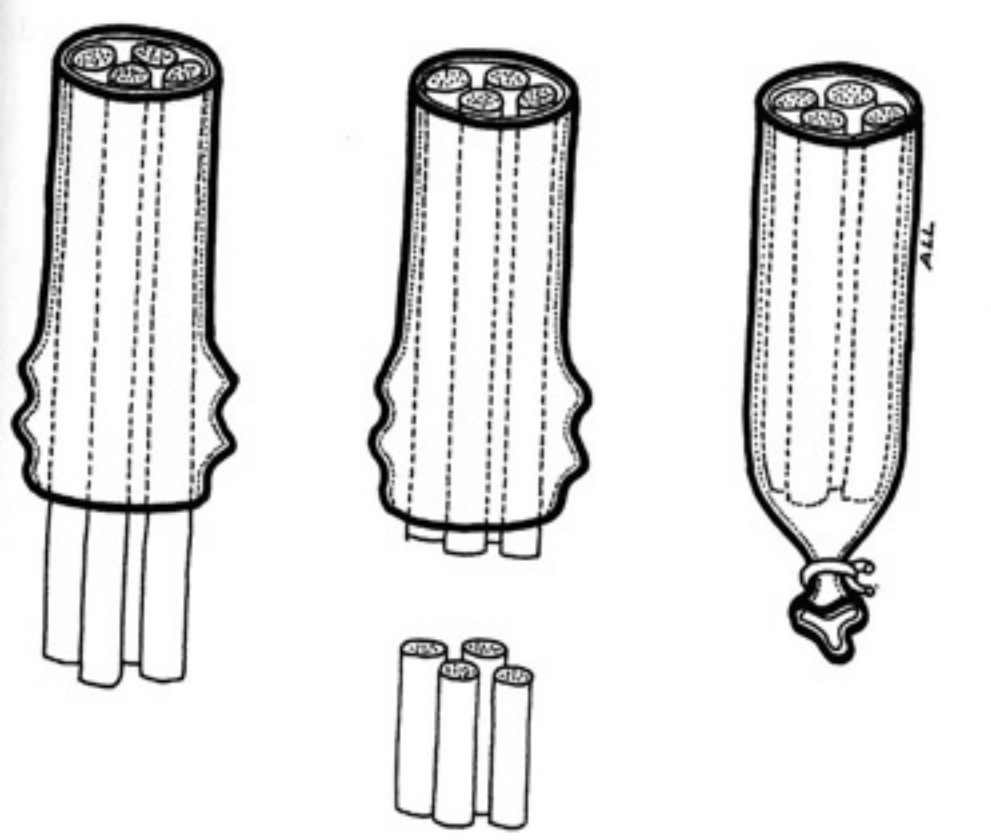

Martini and Fromm, JBJS 71B,1989

- Epineural sleeve sealed with a synthetic tissue adhesive (histoacryl glue)
- 68 neuroma in 36 patients
- All but three improved

Fig. 1
Diagram to show the method of sealing the nerve end with tissue glue.

A NEW OPERATION FOR THE PREVENTION AND TREATMENT OF AMPUTATION NEUROMAS

A. MARTINI, B. FROMM

From the Orthopaedic University Hospital, Heidelberg

A stump neuroma is caused by the disorganised growth of axon cylinders into proliferating granulation tissue, but this is stopped by an undamaged epineural sleeve. We report experiments in the rat in which the epineural sleeve of the stump of the sciatic nerve was freed from nerve fascicles for about 5 mm and then sealed with a synthetic tissue adhesive. Neuroma formation was largely prevented in comparison with the results of other methods.

This new technique has been used to treat 68 painful neuromas in 36 patients. All but three of the patients were cured or improved and none were made worse.

Capping the nerve end

- Sealing the fascicles to prevent axonal escape
- Methyl methacrylate (*Edds, 1945*), silver, lucite, polyethylene, cellophane, vitalium, glass, tantulum, collodium, goldfoil, tin, milipore, silicone, decalcified bone, fascia, vessel wall, placental tissue
- Silicone most effective, 15/18 had pain relief

  Swanson et al, JHS, 1977
- Cap 5X longer than nerve diameter

Silicone Capping

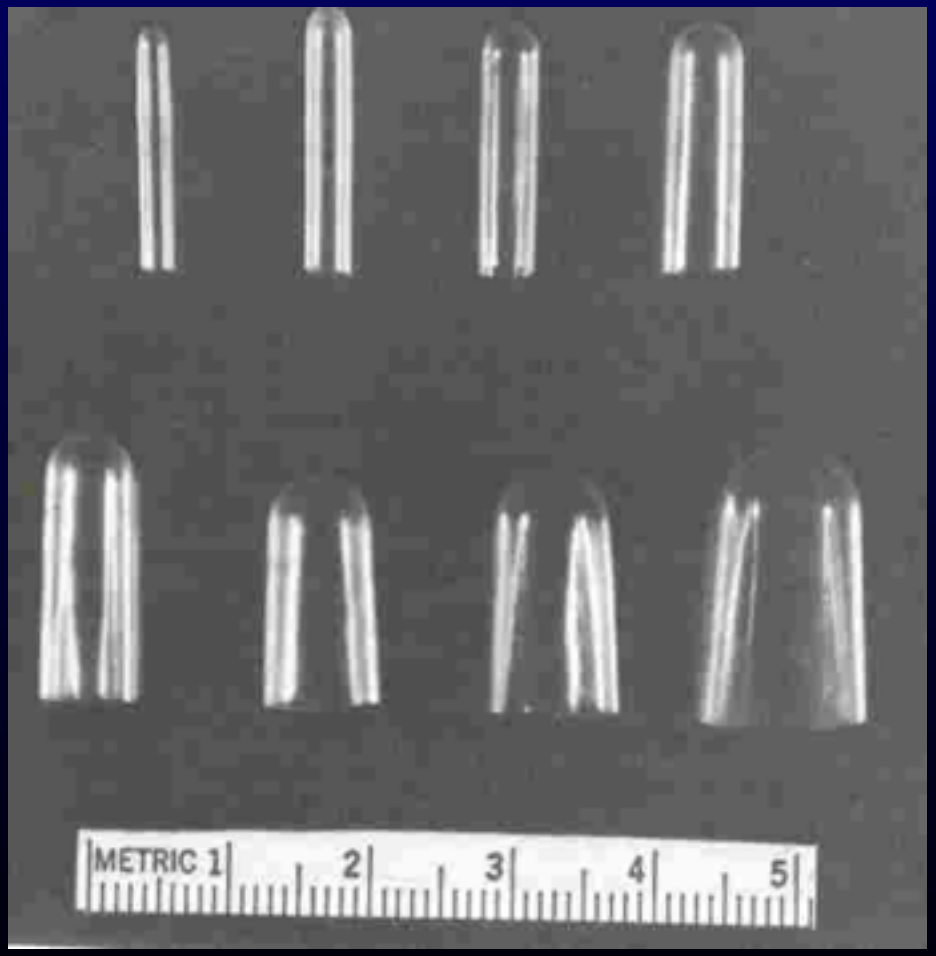

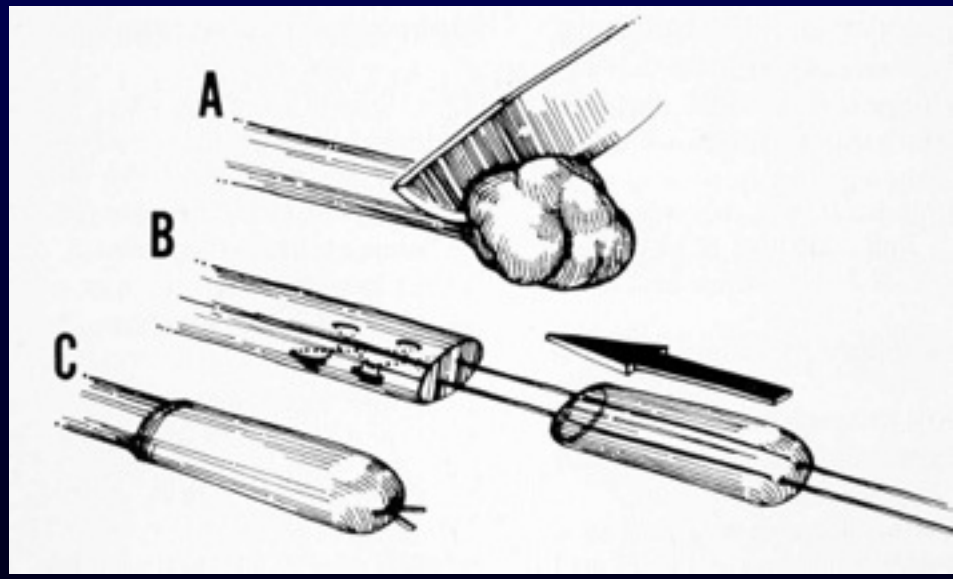

Silicone capping (Tupper and Booth,1976)

- 32 neuromas in 17 patients
- Ducker-Hayes tube and Frackelton cap
- Dislodge in 6 patients
- Nerve fibers had grown through the loose proximal opening in two patients
- 25% excellent results

Silicone Tubing

- Dahlin and Lundborg
  - Silicone tubes at least 20 mm in length
  - No or limited axonal regeneration inside
  - Proximal nerve end extends only a few mm
  - Forms a con-shaped structure, non painful
  - “Most” patients exhibited some relief

Dahlin LB, Lundborg G: Use of tubes in peripheral nerve repair, *Neurosurg Clin North Am* 12:341-352, 2001.

Centro-central Nerve Union

- Single neuroma
- Dissection of different nerve fascicles followed by an end to end repair of 2 groups of fascicles of similar diameter.
- Increased pressure and inhibit protein production
- Must be perfect match in order to succeed

Centro-central Loop Coaptation

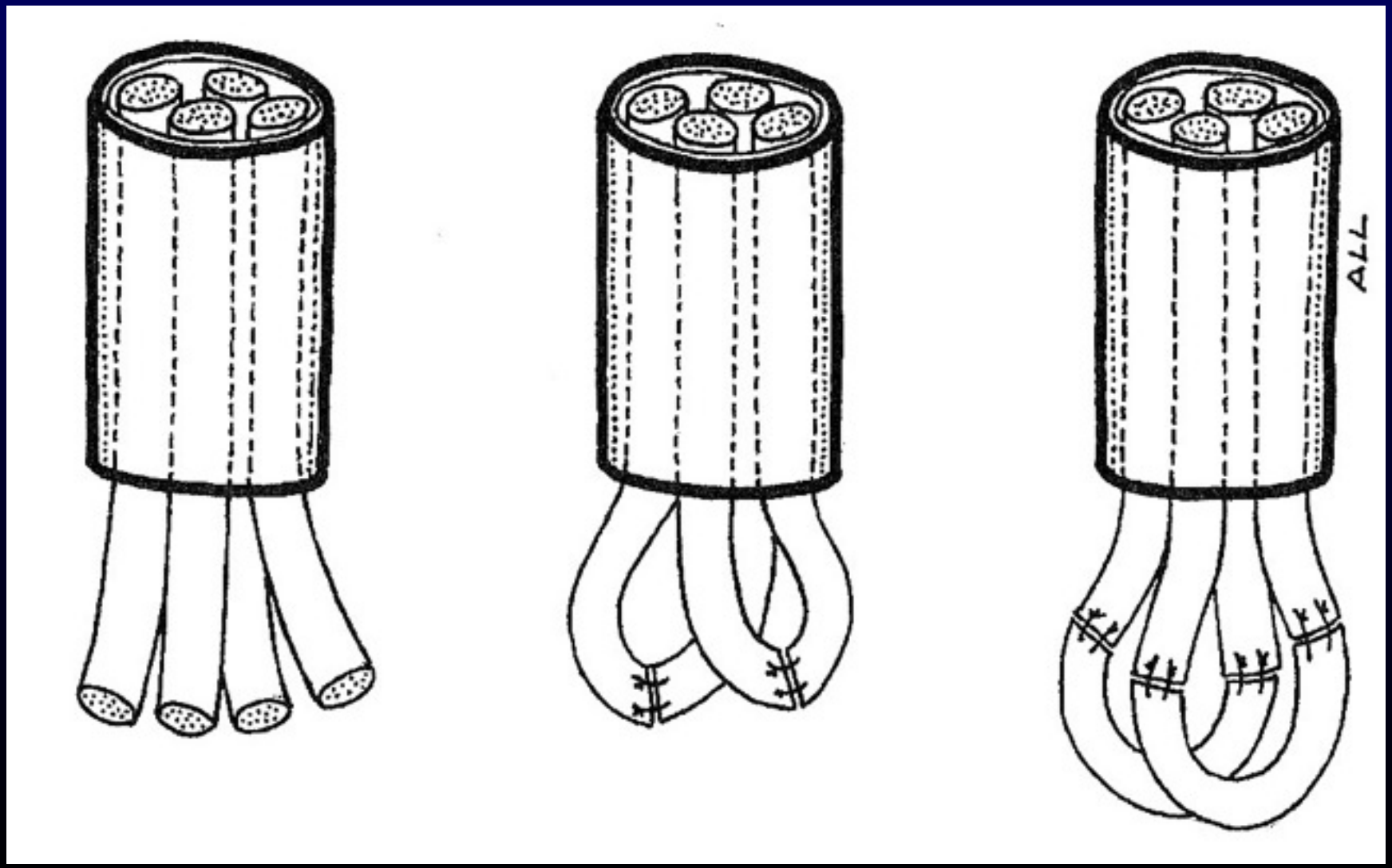

J Neurosurg 79:331–334, 1993

Centrocentral anastomosis of the proximal nerve stump in the treatment of painful amputation neuromas of major nerves

JOSÉ BARBERÀ, PH.D., AND RAFAEL ALBERT-PAMPLÓ, PH.D.

Department of Neurosurgery, Hospital General Universitario, Excma. Diputación de Valencia, and Centro de Rehabilitación de Levante, Paterna, Valencia, Spain

✓ The term "centrocentral anastomosis" is used to describe the end-to-end connection across interposed nerve grafts between paired fascicular groups of the proximal stump of a severed nerve. In 22 patients harboring a painful terminal neuroma following amputation of a lower limb (20 neuromas on the sciatic nerve and two on the peroneal nerve), a centrocentral anastomosis was performed on the end of the sectioned nerve to treat pain that had not improved with conventional conservative treatment. Follow-up review at 1 year revealed that the typical neuroma pain had disappeared in all cases, although sporadic diffuse pain persisted in four. Where previous phantom sensation was present, no change was observed. The results presented here are consistent with laboratory findings demonstrating the absence of neuroma formation after centrocentral anastomosis. Therefore, this technique is recommended for the treatment of painful amputation neuroma.

KEY WORDS · **centrocentral anastomosis** · **amputation neuroma** · **pain** · **peripheral nerve**

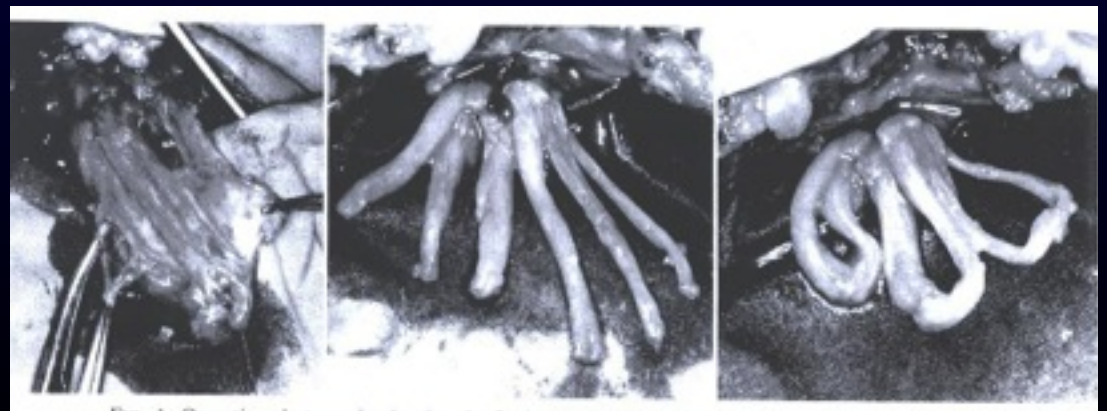

FIG. 1. Operative photographs showing the fascicular dissection of the nerve stump after excision of the neuroma *(left)*, six individualized fascicular groups *(center)*, and centrocentral anastomosis of the fascicular groups before connecting the nerve with biological adhesive *(right)*.

The Treatment of Amputation Neuromas in Fingers with a Centrocentral Nerve Union

Moshe Kon, M.D., Ph.D.*
Joannis J. A. M. Bloem, M.D., Ph.D.†

The centrocentral nerve union with an interposed autologous nerve graft was used for the treatment of 32 symptomatic neuromas in the fingers of 18 patients. The technique was applied to bilateral as well as unilateral neuromas, using the dorsal branch of the proper digital nerve in the latter. All 18 patients showed definite objective and subjective improvement, and no loss on the early result (approximately thirty-six weeks) was found in the remainder of the follow-up (average, eighteen months).

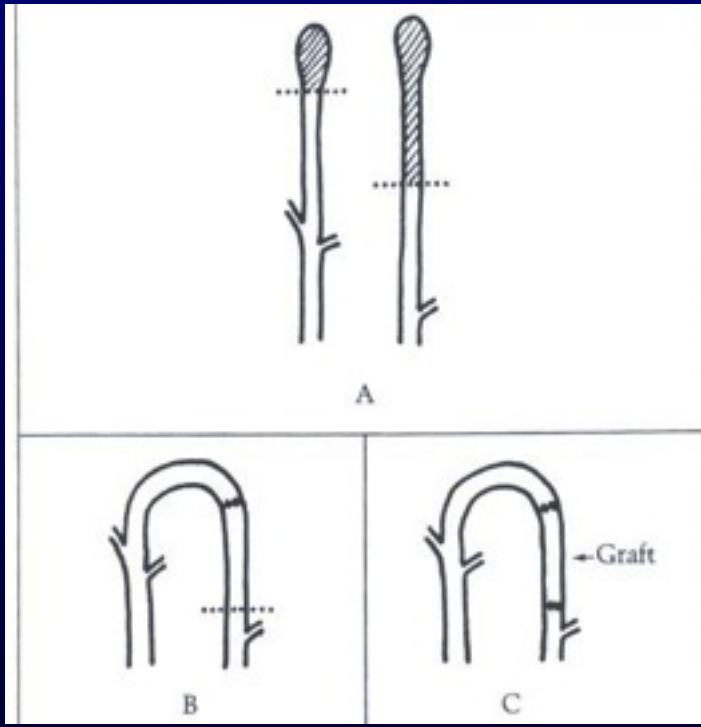

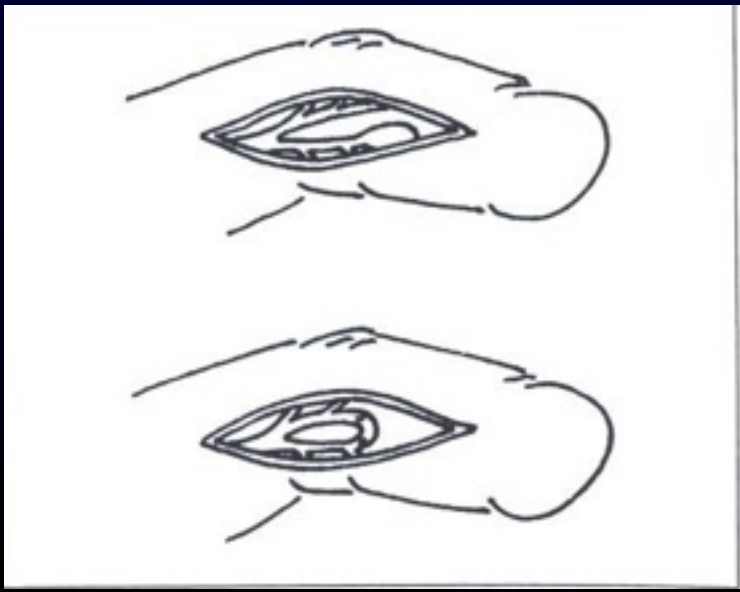

Excision of two neuroma and end to end repair

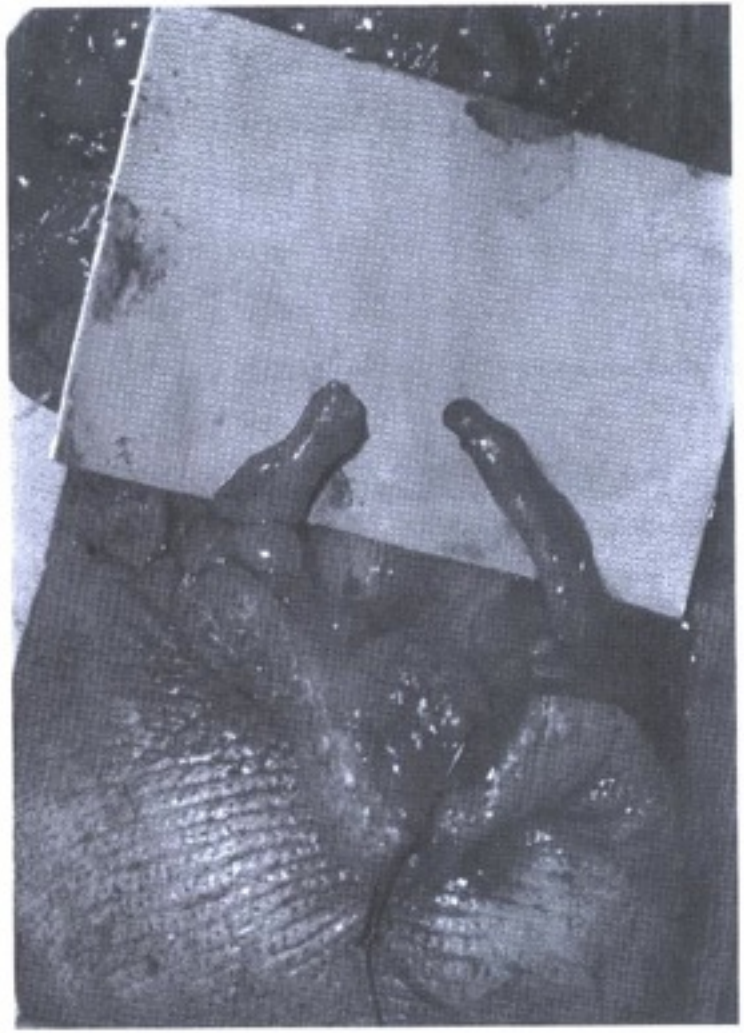

Fig 1 Nerves dissected out prior to randomization.

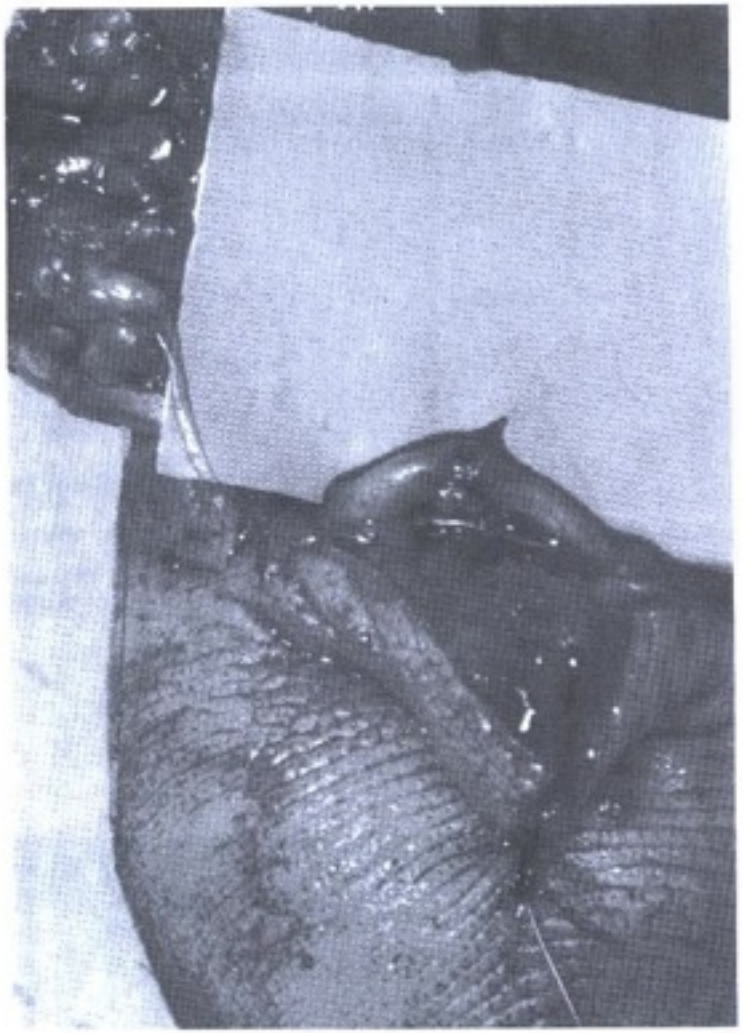

Fig 2 Centro-central union.

Collagen Conduits

- Thomsen et al
  - 10 digital neuromas with distal stumps present
  - Excised with interposed collagen conduits
  - No recurrence of pain
  - Quick-Dash: 19.3
  - Cold Intolerance Symptom Severity: 27.8

Thomsen L, et al. Treatment by collagen conduit of painful post-traumatic neuromas of the sensitive digital nerve: A retrospective study of 10 cases. Chirurgie de la main 29 (2010) 255–262

Toe-to-Thumb Transfer

- Toe-to hand transfer has been used successfully in the treatment of thumb lost and painful neuroma in the finger

Foucher, 1984

- Allow the regenerating axon to grow into the donor nerve of the toe

Foucher et al, JHS, 1991

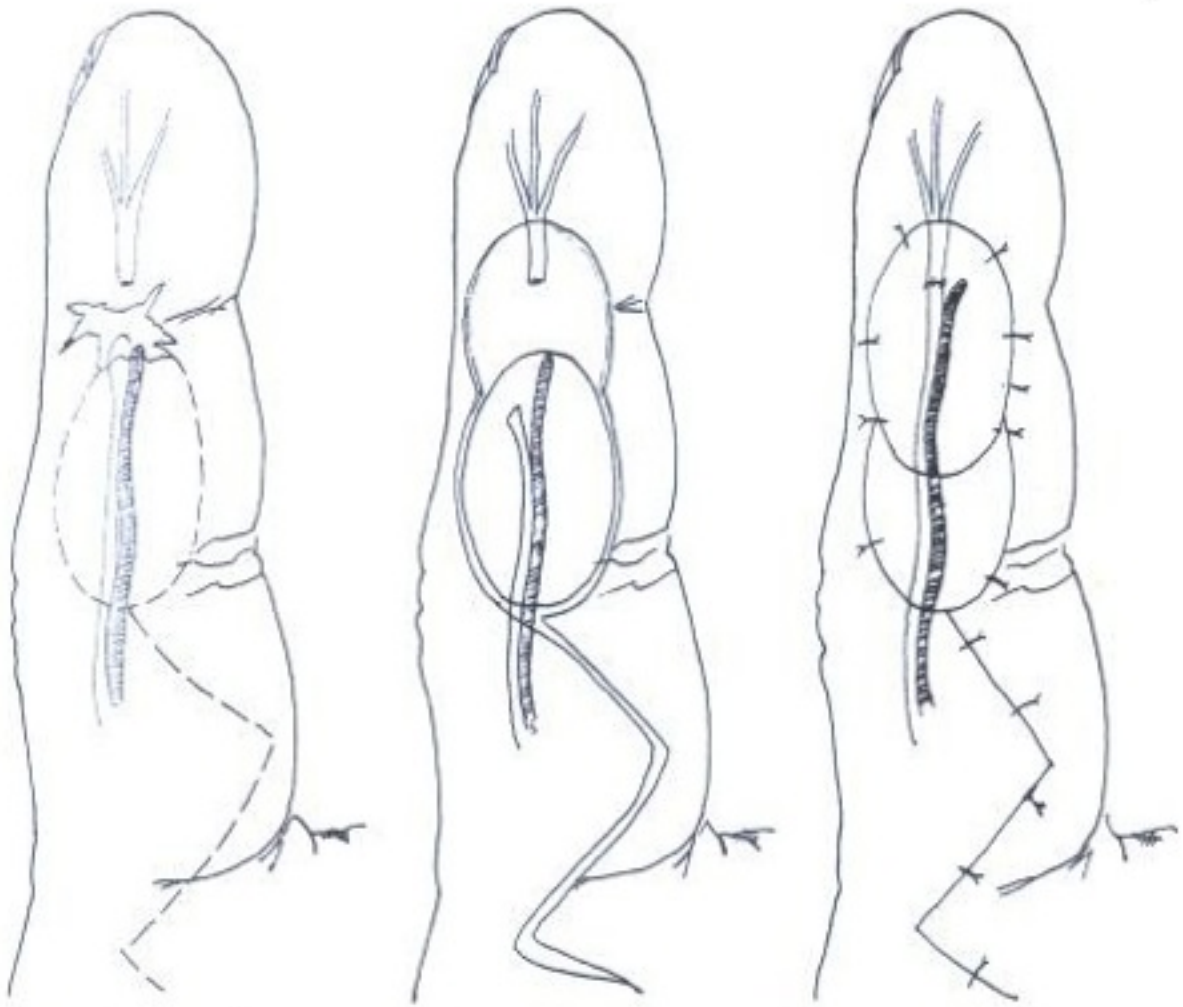

Fig. 3 Lasso island flap with proximal island flap. Neuroma and scar excision followed by advancement of the flap and nerve suture.

Foucher et al, JHS, 1991

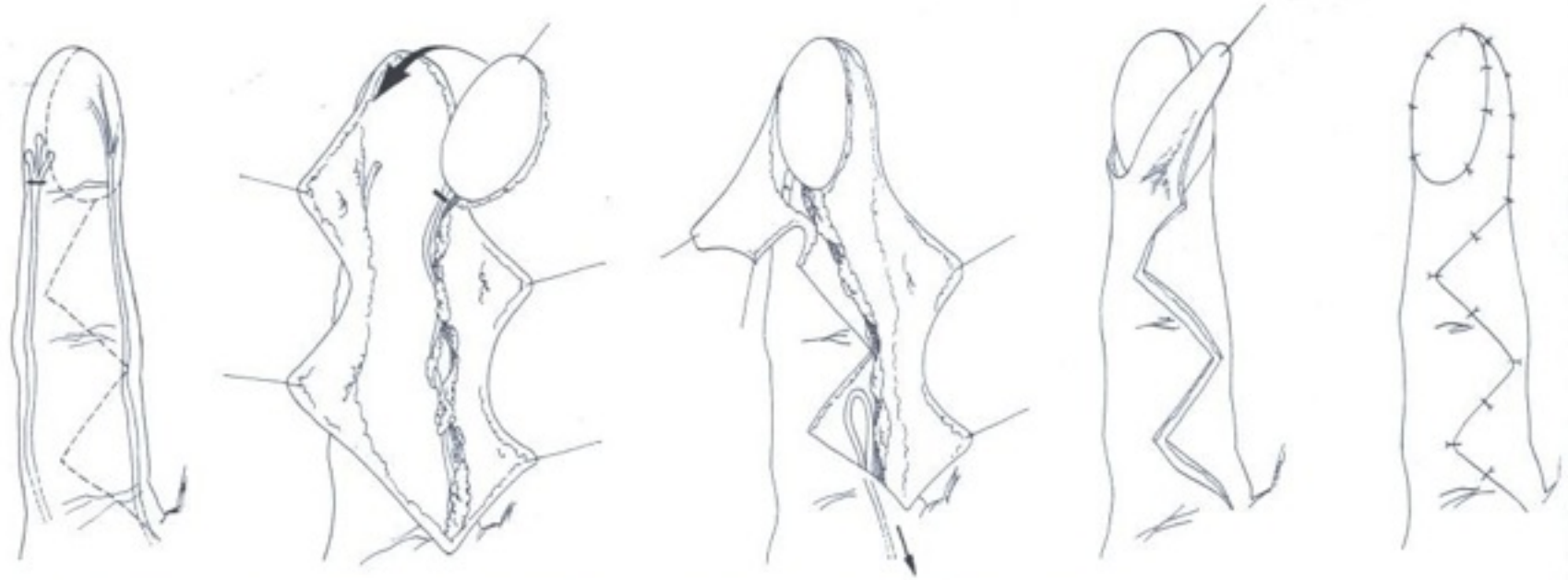

Fig. 2 Resection of the neuroma on the radial border of an index and radially based skin island flap.

Methods to Protect Neuroma from Mechanical Irritation

- Simple resection
- Transposition
- Relocation
- Implantation
- Capping

Resection

- 316 neuromas
- 36.5% excellent results after single resection
- 45% excellent after second resection

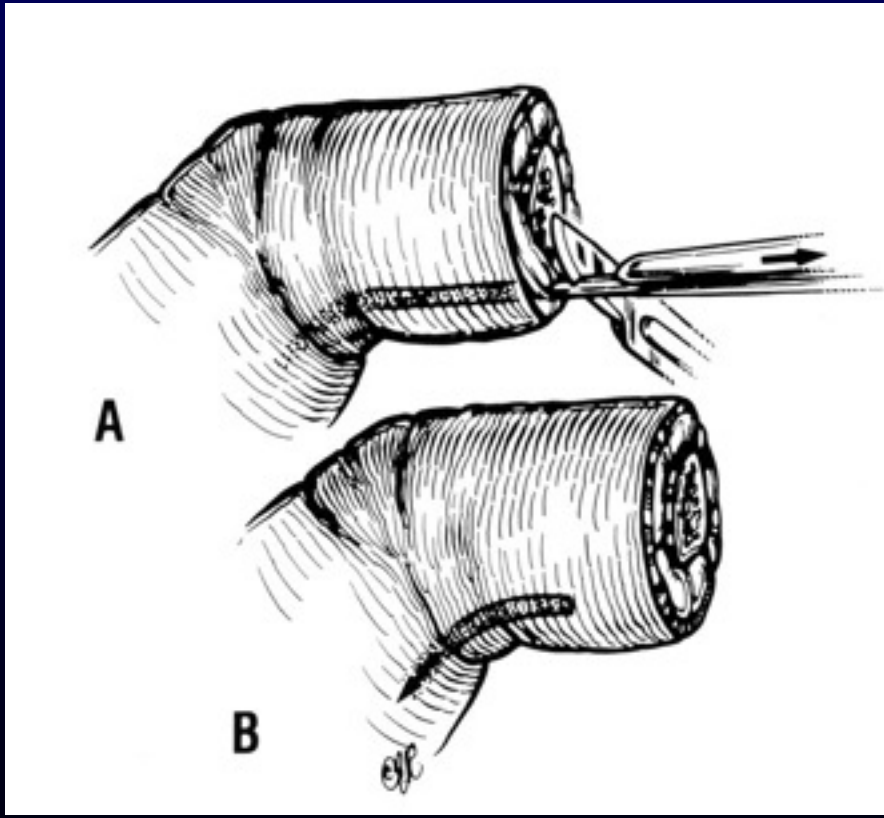

Tupper and Booth, JHS, 1976

Transposition with implantation

- Neuroma is excised and stump implanted into other tissues
- Implantation into the same nerve (Neurocampsis)
- Implantation into muscle/freeze-thaw method
- Implantation into bone
- Implantation into another nerve
- Implantation into vein

Implantation into same nerve (Neurocampsis)

- Implanted into nerve trunk proximally through an opening in the epineurium
- Larger neuroma

  Petropoulos and Stefanko, 1961
- Successful in 6 patients

  Ashley and Stallings,1988

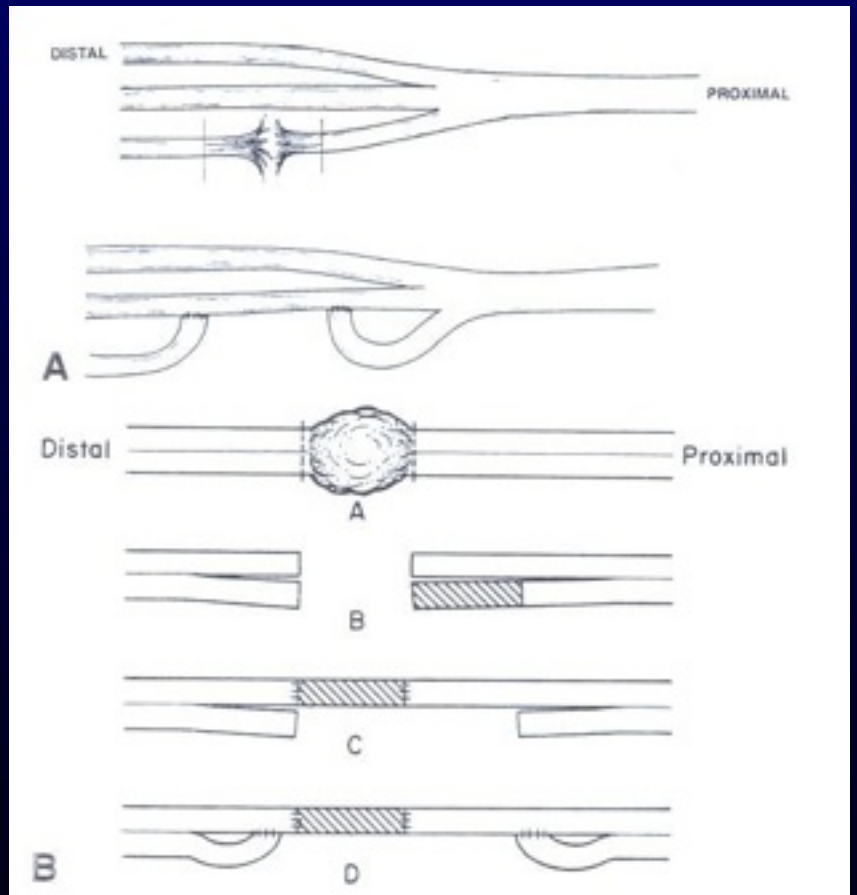

Figure 6. The two techniques proposed for the prevention and treatment of painful neuromas using the end-to-side nerve repair concept. ***A:*** *An injury affecting one branch of the superficial radial nerve.* ***B:*** *A neuroma of the main trunk of the superficial radial nerve.*

Implantation into Muscle

- Protects terminal nerve end and inhibits neuroma formation
- First reported clinical use *Moszkowicz, 1918*
- Absent or minimal neuroma formation

  Petropoulos and Stefanko, 1961
- 78 neuromas F/U 31mon, 82% success rate

  Dellon and Mackinnon, PRS,1986

Dellon and Mackinnon, PRS,1986

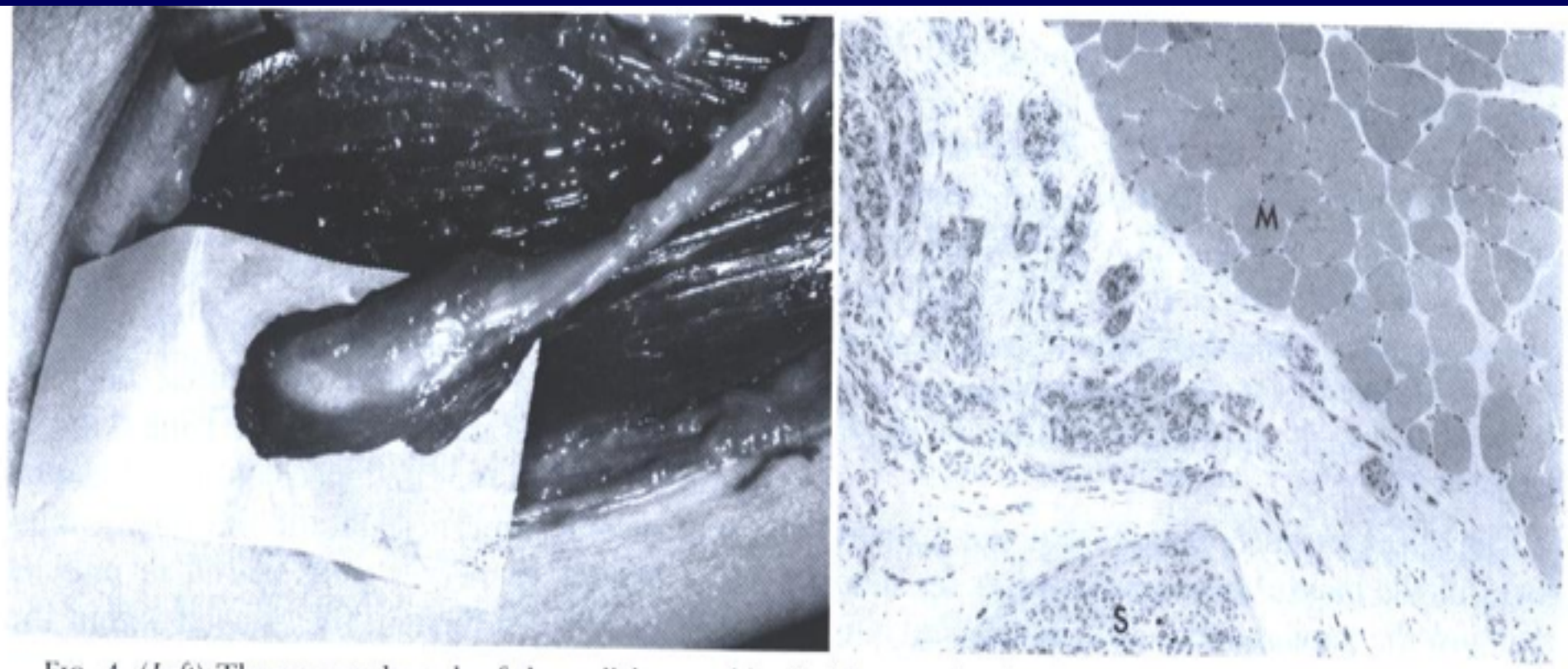

FIG. 4. (*Left*) The sensory branch of the radial nerve biopsied 1 year after implantation into the brachioradialis muscle tapered smoothly within the muscle and did not appear to invade through the muscle but was surrounded by a cap of muscle tissue. (*Right*) In the muscle bed, the sensory nerve preserves its normal architecture. A small neuroma, not invading the muscle, is apparent at the nerve-muscle junction (*S*, sensory nerve; *M*, muscle) (toluidine blue; ×153).

Implantation into Muscle

- Avoid burying the nerve too superficially or in muscle with large excursion
- 39% excellent & 49% good results in treating superficial radial nerve neuroma
- Recommended burying the nerve in the brachioradialis

Freeze-Thawed Muscle Graft

- Thomas et al
  - 22 neuromas, 20 pts
  - Pain improved
    - 11/15 in the UE
    - 2/7 in the LE

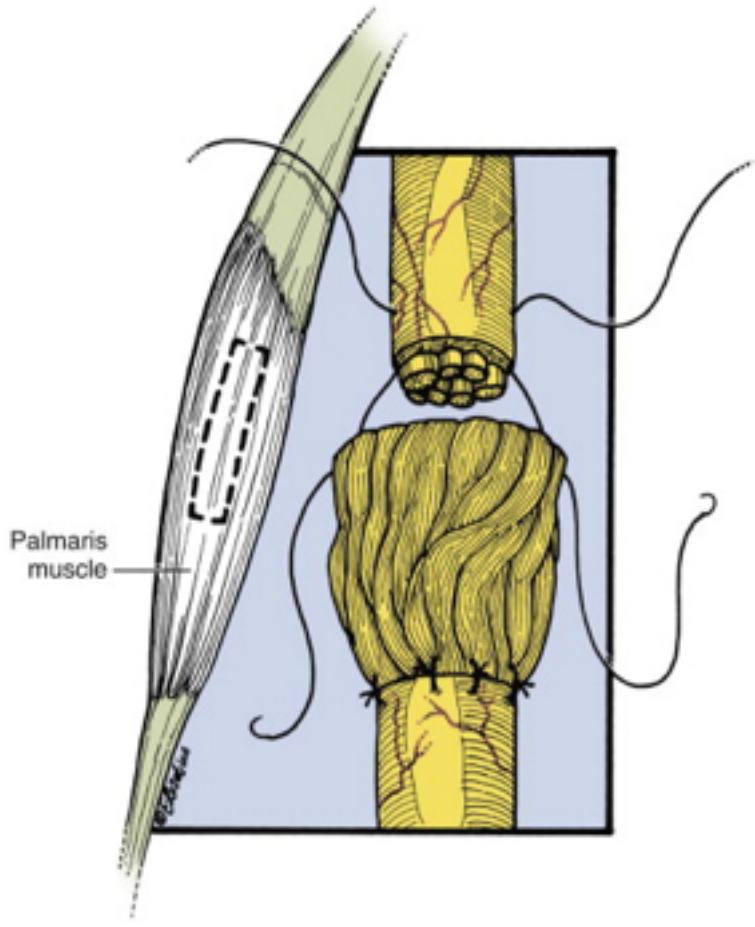

Thomas M, Stirratt A, Birch R, et al: Freeze thawed muscle grafting for painful cutaneous neuromas, *J Bone Joint Surg Br* 76:474-476, 1994.

TREATMENT OF END-NEUROMAS, NEUROMAS-IN-CONTINUITY AND SCARRED NERVES OF THE DIGITS BY PROXIMAL RELOCATION

A. HAZARI and D. ELLIOT

From the Hand Surgery Department, St. Andrew's Centre for Plastic Surgery, Broomfield Hospital, Chelmsford, Essex, UK

This paper reports the results of treatment by proximal relocation of 104 painful nerves in 57 digits in 48 patients. These included 86 digital nerves and 18 terminal branches of the superficial radial nerve and the dorsal branch of the ulnar nerve. Eighty-three were end-neuromas and 14 were neuromas-in-continuity, of which nine followed nerve repair and five occurred following a closed crush injury. Seven were painful as a result of tethering in scarred tissue.

Eighty nerves (77%) required a single relocation and 24 (23%) required more than one operation. Ninety-eight per cent of nerve relocations achieved complete pain relief at the primary site. One patient had mild pain on pressure at the primary site after relocation of two nerves from this site. Over 90% of the nerves had no spontaneous pain, pain on movement or hypersensitivity of the overlying skin at the final site of relocation. However, the incidence of mild or no pain on direct pressure at the site of nerve relocation was lower at 83% as relocated nerves, although traumatized less often at the sites chosen for relocation, can still be painful on direct pressure.

Journal of Hand Surgery (British and European Volume, 2004) 29B: 4: 338–350

Keywords: nerve pain, end-neuroma, neuroma-in-continuity, scarred nerve, nerve relocation

Sood and Elliot, JHS, 1998

g 1 Zones of the hand as a guide to relocation of painful nerves of the hand and wrist. *Zone* 1 – *the digits*: Pain from the digital nerves, their dorsal branches and the terminal branches of the nerves innervating the dorsum of the hand. First choice of relocation – the proximal phalanx or metacarpal. *Zone* 2 – *the body of the hand*: Pain from the common digital nerves, the palmar cutaneous branches of the median and ulnar nerves and the dorsal branch of the ulnar nerve. First choice of relocation – pronator quadratus muscle. *Zone* 3 – *the radial border of the wrist and the forearm*: Pain from the superficial radial nerve, the lateral cutaneous or antebrachial nerve of the forearm, the medial cutaneous nerve of the forearm and the posterior cutaneous nerve of the forearm. First choice of relocation – muscles of the forearm and arm, especially brachioradialis.

Implantation into bone

- Rationales:
  1. To contain the nerve stump in rigid compartment, thereby restricting the neuroma size
  2. To protect the neuroma from direct trauma

- Adequate mobilization of nerve with no tension
- Avoid excessive angle into bone
- No implantation of nerve distal to joint

Implantation into bone

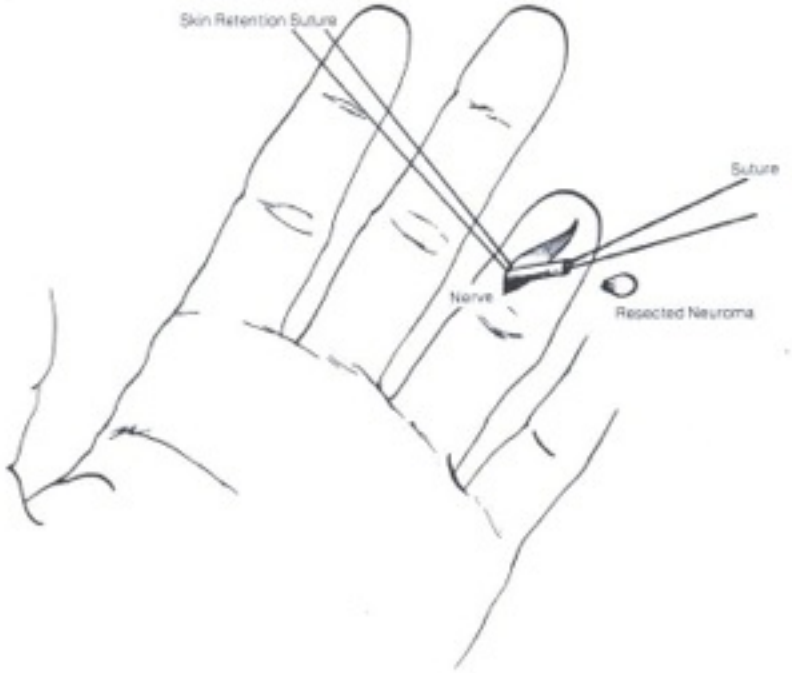

Fig. 1. Dissection of digital nerve with neuroma through a midaxial incision, which mobilizes the nerve in a proximal direction and resects the neuroma.

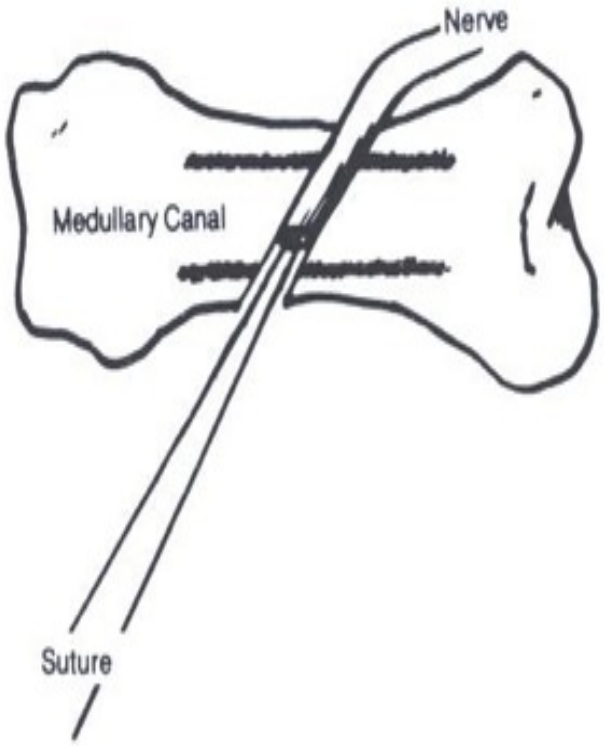

Fig. 2. Distal end of the nerve is introduced into medullary canal of the diaphysis of the long bone, with the retention suture passing through the opposite cortex.

Implantation into bone

- 18 successful results in 20 neuromas

  Mass et al, PRS, 1984

- Excellent or satisfactory results in 10 of 11 cases

  Goldstein and Sturim, JHS, 1985

VEIN IMPLANTATION FOR TREATMENT OF PAINFUL CUTANEOUS NEUROMAS

A preliminary report

T. J. HERBERT and S. L. FILAN

From St Luke's Hospital Hand Unit, Sydney, Australia

Based on the theory that recurrent neuroma formation can be prevented if the cut nerve end is implanted into the lumen of a vein, 14 patients have been treated by neuroma excision followed by proximal vein implantation over the last 5 years. Thirteen patients reported dramatic pain relief following surgery, and this was sustained in all but one case. Both failures were re-explored, when it was found that the nerve had pulled out of the vein, leading to recurrent neuroma formation. Both cases were revised successfully using the same technique. With a mean follow-up of 15 months, 11 patients remain symptom-free, whilst three have minor residual symptoms which are not severe enough to require further surgery.

Journal of Hand Surgery (British and European Volume, 1998) 23B: 2: 220–224

Relocation

- Keep neuroma intact with its mature encapsulating scar
- Transpose en bloc to an adjacent area free of scar and not subjected to repeated trauma
- 82% of amputation neuroma and 63% of terminal branch neuroma had excellent results

Hermann et al, 1945

Karev & Stahl, JHS, 1986

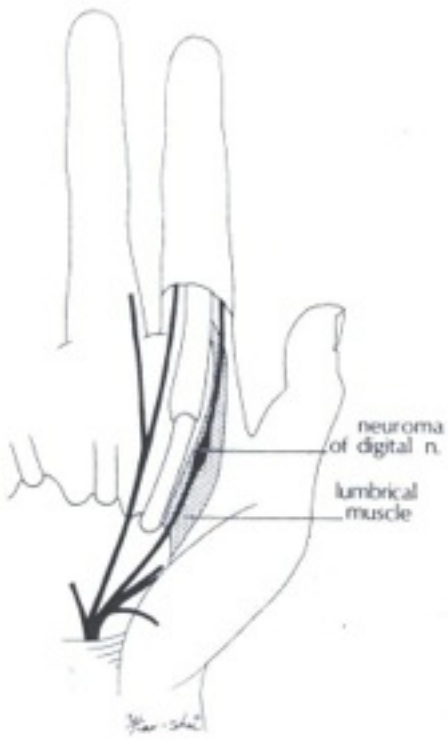

Fig. 1. Normal anatomic relation between the digital nerve and the lumbrical muscle.

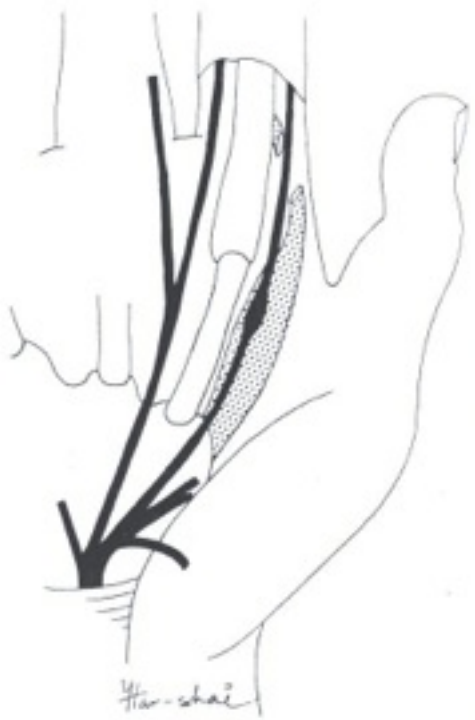

Fig. 2. Tenotomized lumbrical muscle.

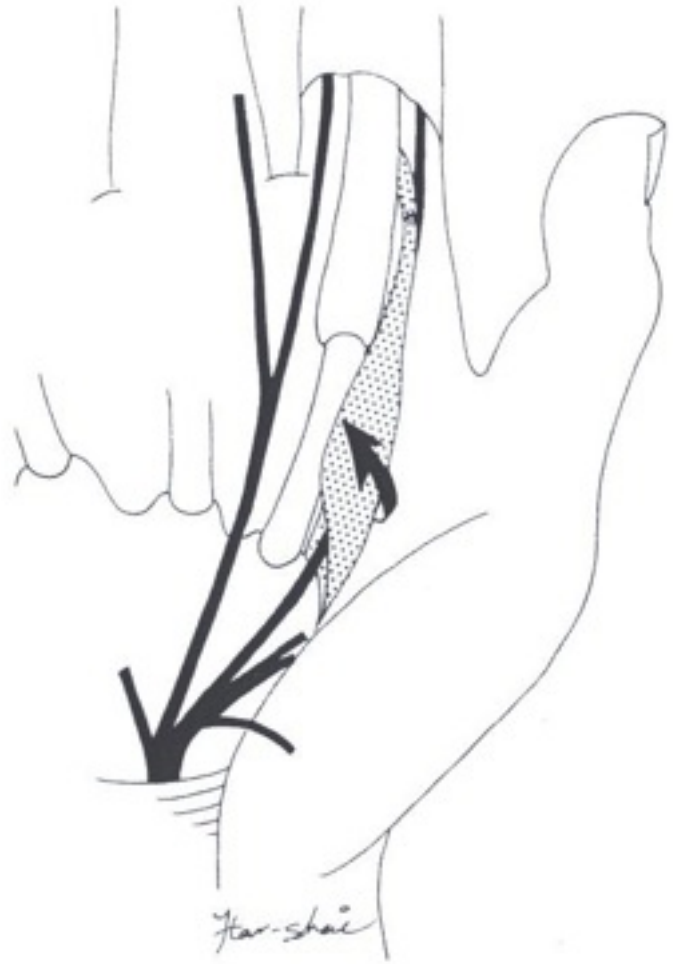

Fig. 3. The rerouted digital nerve under the replaced lumbrical muscle.

Role of neurolysis in neuroma in continuity

- External neurolysis in the mixed nerve preserved function
- Internal neurolysis if no resolution of pain for 3 to 6 months
- Resection if nerve has no vital role

Burchiel & Ochoa, 1991

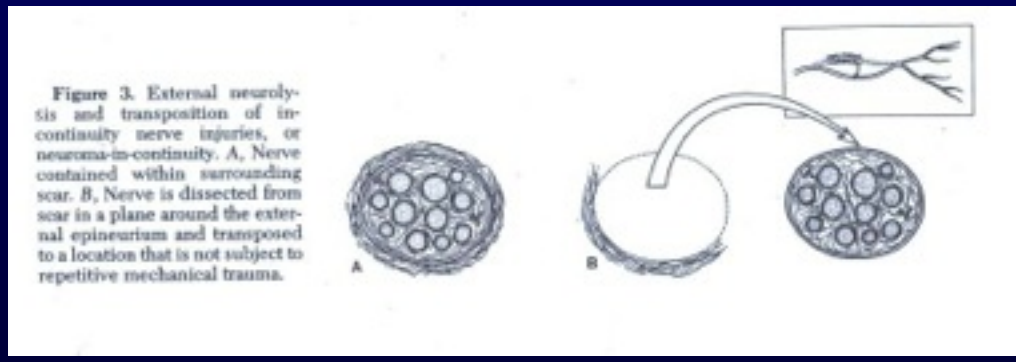

Figure 3. External neurolysis and transposition of in-continuity nerve injuries, or neuroma-in-continuity. *A*, Nerve contained within surrounding scar. *B*, Nerve is dissected from scar in a plane around the external epineurium and transposed to a location that is not subject to repetitive mechanical trauma.

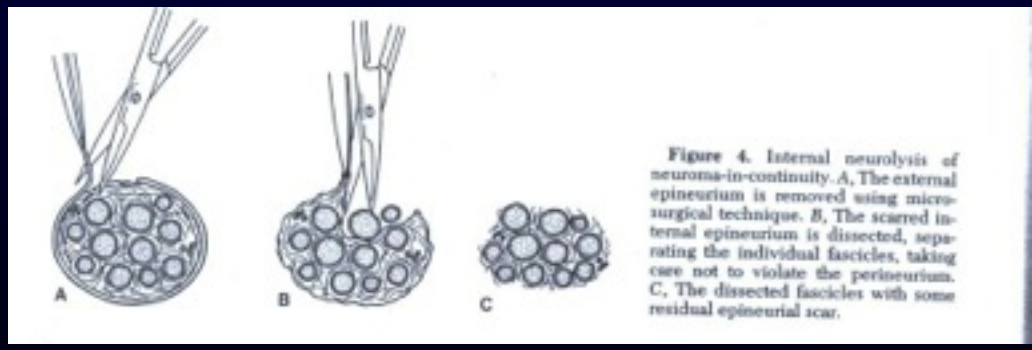

Figure 4. Internal neurolysis of neuroma-in-continuity. *A*, The external epineurium is removed using microsurgical technique. *B*, The scarred internal epineurium is dissected, separating the individual fascicles, taking care not to violate the perineurium. *C*, The dissected fascicles with some residual epineurial scar.

Post operative treatment

- Consider indwelling catheter
  - Bolus infusions of local anesthetic
  - 48 hours
- Immediate motion
  - Nerve gliding
  - Scar prevention

Summary

- Painful neuroma may impair the function of the whole hand
- Diagnosis is by clinical and careful evaluation is important
- The optimum management still unknown