Muscle Flaps

History

- Tansini (1896): pedicled latissimus dorsi

I Tansini. Nuovo processo per l'amputazione della mammella per cancro. Reforma Medica. 12:3 , 1896

History: why the void?

- **Olivari** (1976): rediscovered LD

"I should not care to say Beware of the man with the plastic operation . . . But to attempt to close the breast wound more less regularly by any plastic method is hazardous, and in my opinion, to be vigorously discountenanced"
Halsted[23]

Halsted WS. The results of surgical operations for the cure of the cancer of the breast. Tr AM Surg. A 25: 61, 1907

History

- **Owen**(1955), **Bakamjian** (1963): SCM flap
- **Ortichochea** (1972): gracilis mc flap
- **Baudet** (1976): term musculocutaneous flap
- **Nahai** (1978):TFL
- **Mathes-Nahai** classification of muscle vascularization (1979)

The basics

1- Safety = successful wound coverage

- *accessible* muscle
- *adequate size* (pedicle and flap);
- the vascular *pedicle easily located*, *constant* and *adequate*.
- adequate arc of rotation

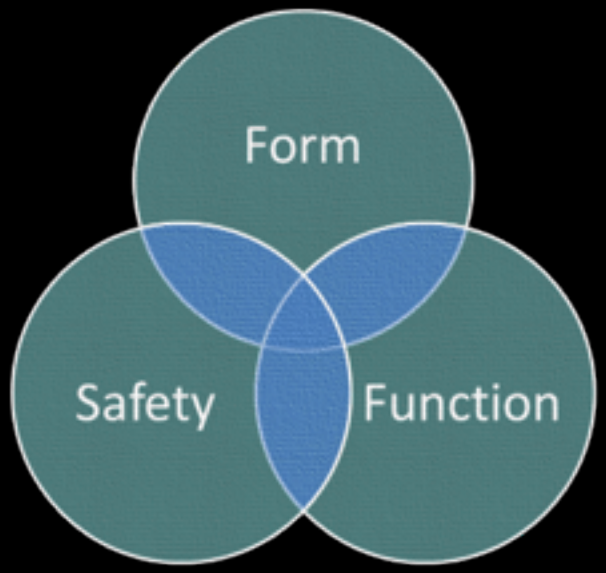

The basics

2- Form- normal shape or contour

- **Restoration** at defect
- **Preservation** at donor site:

✓ spendable muscle

✓ uninjured adjacent muscle groups

✓ segmental muscle transfer)

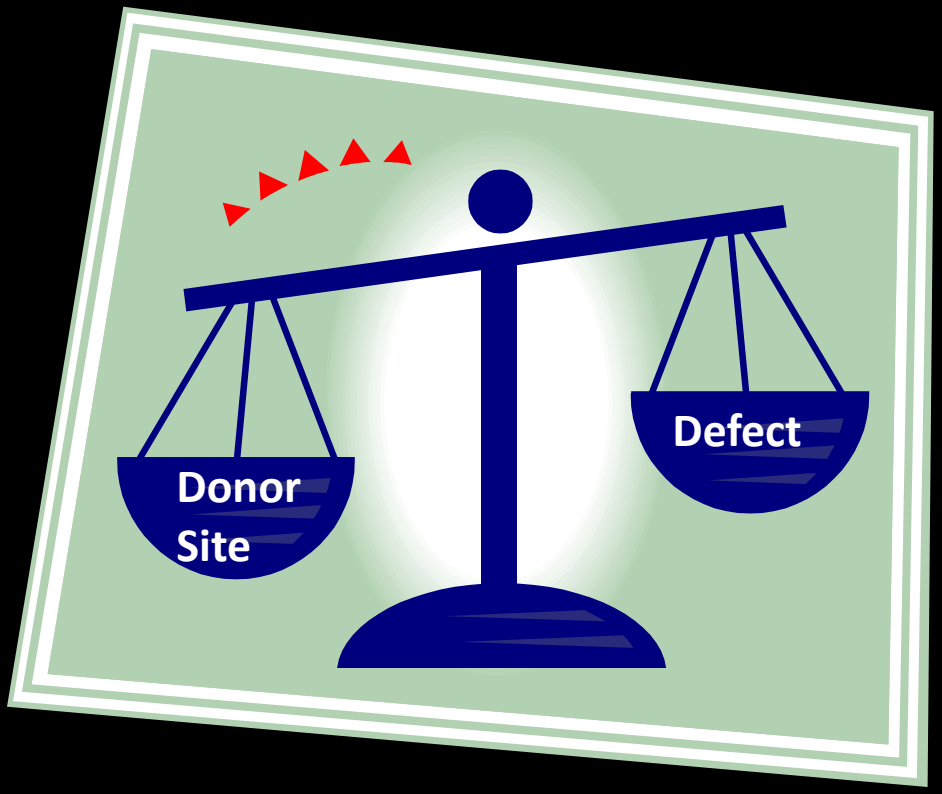

The basics

- Function – stable closure, specialized functions.
  - Sensation
  - Skeletal Support
  - motion (or animation)

Classification and Flap selection

Mathes-Nahai Classification

- Major pedicle
- Minor pedicle
- Dominant pedicle
- Segmental Pedicles
- Choke arteries
- Oscillating veins

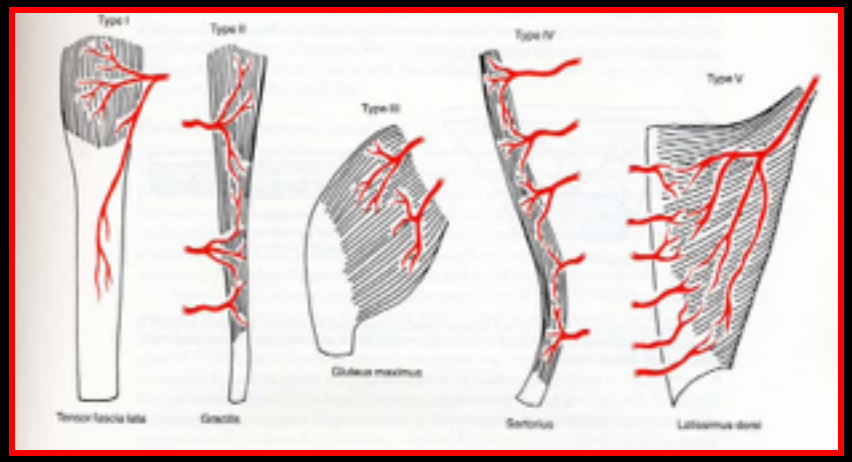

Mathes SJ, Nahai F. Classification of the vascular anatomy of muscles: experimental and clinical correlation. Plast Reconstr surg. 67:177, 1981

Type I

- Single vascular pedicle
  - **<u>Tensor fascia Lata</u>**
  - **<u>Gastrocnemius</u>**

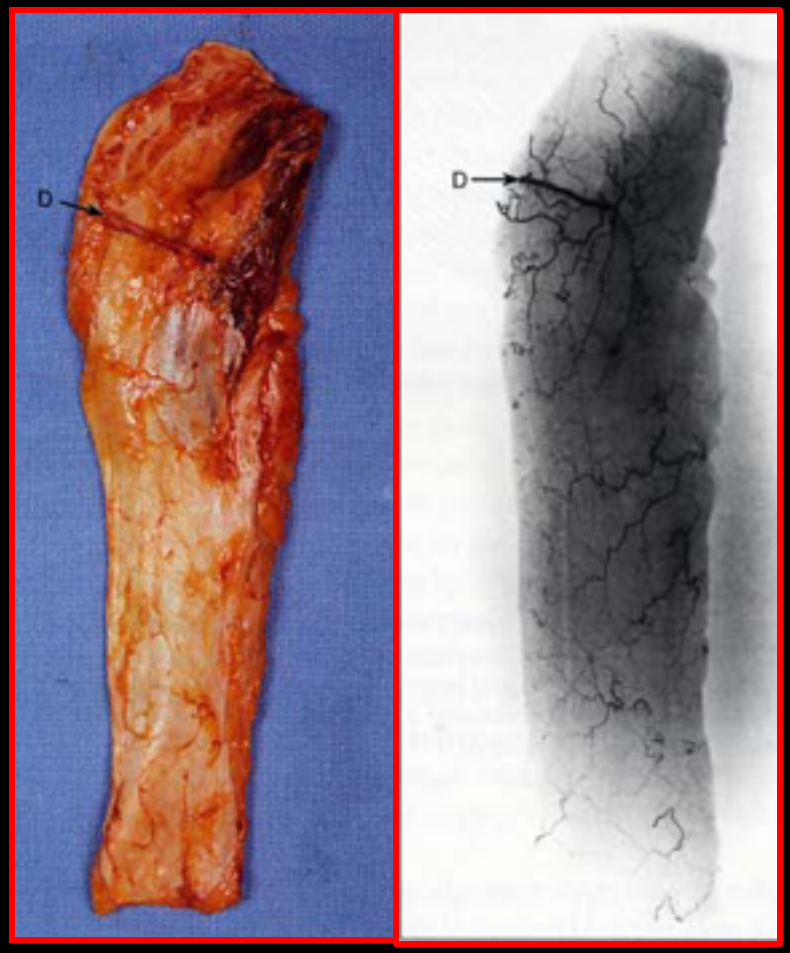

Type II

- Dominant Vascular Pedicle and Minor Pedicles
  - **<u>Gracilis</u>**
  - **Trapezius**
  - **Soleus**
  - **Rectus femoris**
  - **Brachioradialis**

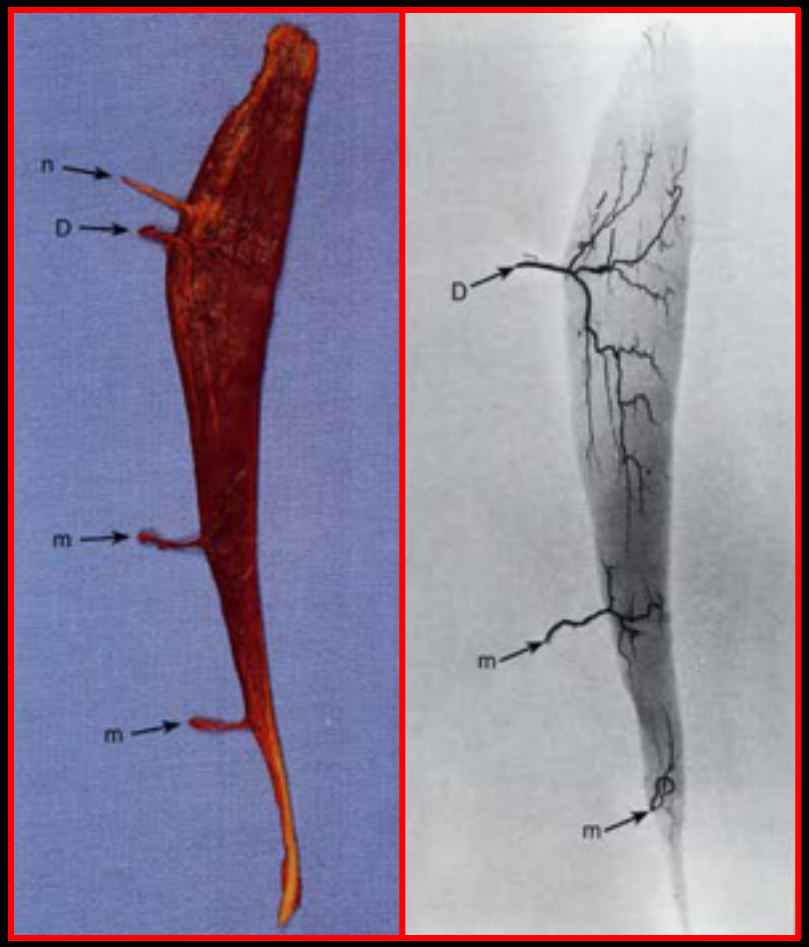

Type III

- Two Dominant Pedicles
  - **Gluteus Maximus**
  - **Rectus abdominis**
  - **Serratus anterior**

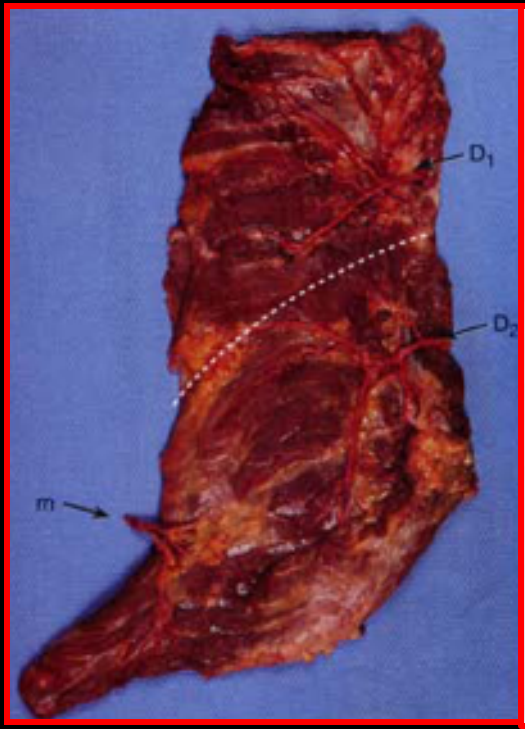

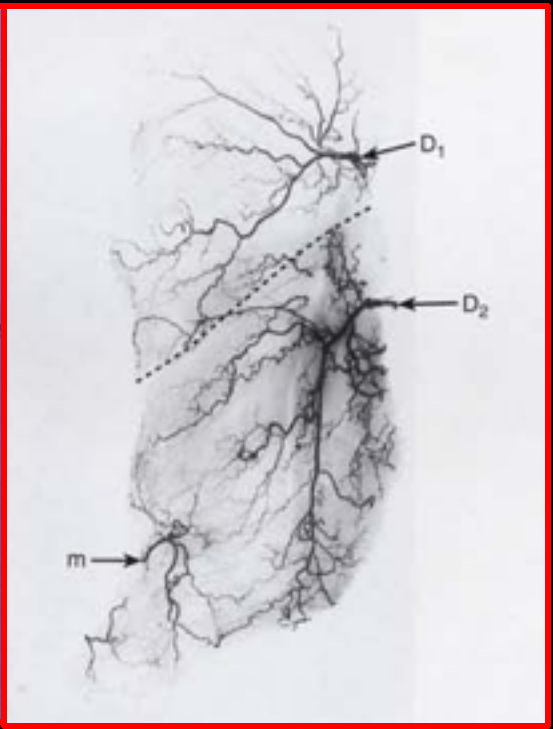

Type IV

- Segmental Pedicles
  - Sartorius
  - Tibialis Anterior

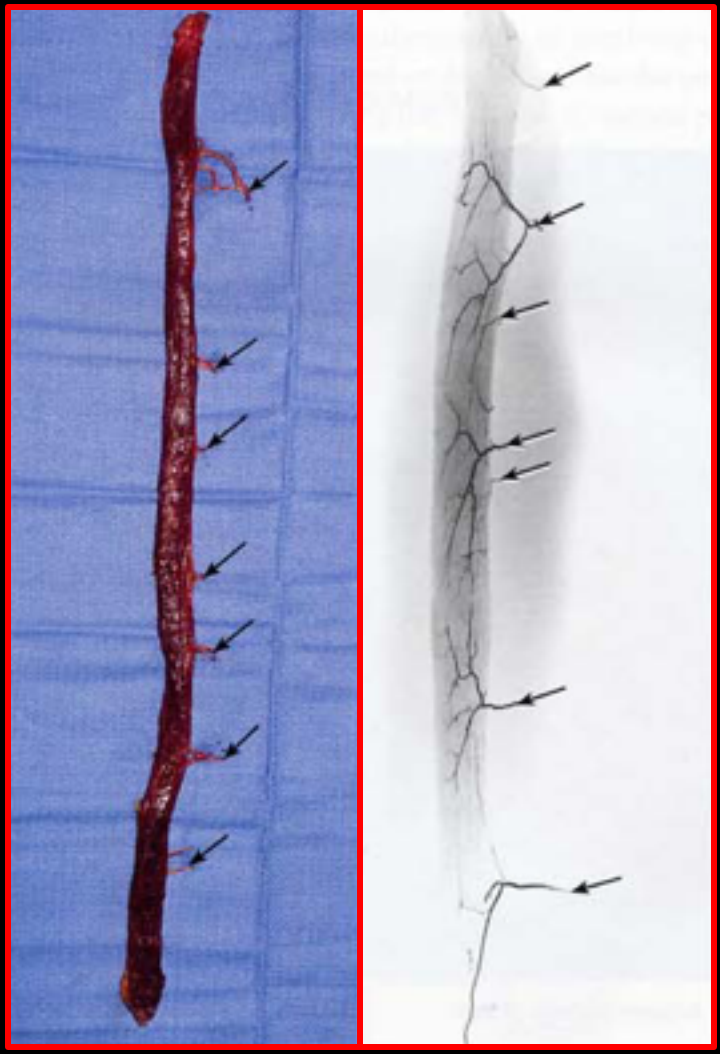

Type V

- Single Dominant and secondary segmental pedicles.
  - **Latissimus Dorsi**
  - **Pectoralis Major**

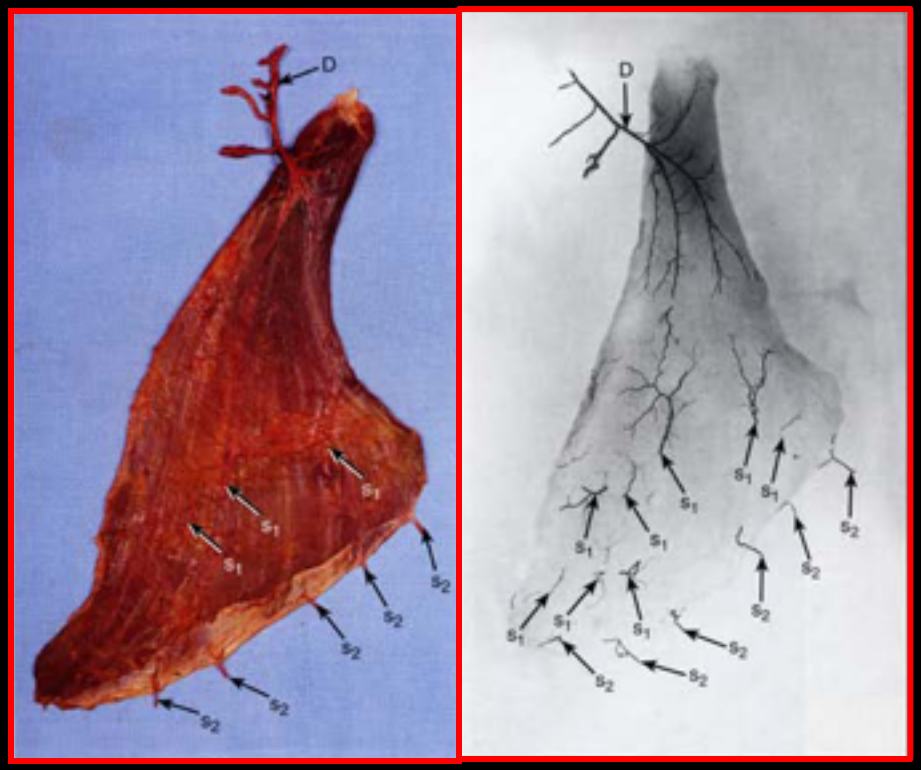

Venous anatomy

- The venous territories match the arterial territories.
- choke arteries =oscillating veins
- the valves of adjacent territories direct away from each other and towards their respective pedicles.
- **afferent veins** : enter many muscles from the superficial (musculocutaneous perforators) and deep tissues.
- **Efferent veins**: contain valves and drain the muscle into the parent veins

Taylor GI. The venous territories (venosomes) of the human body: experimental study and clinical implications. Plast Reconstr Surg.1990 Aug; 86(2):185-213.

Classification

- Type I: single venous territory draining in 1 direction
- Type II: 2 territories draining in opposite directions
- Type III: 3+ territories draining in multiple directions

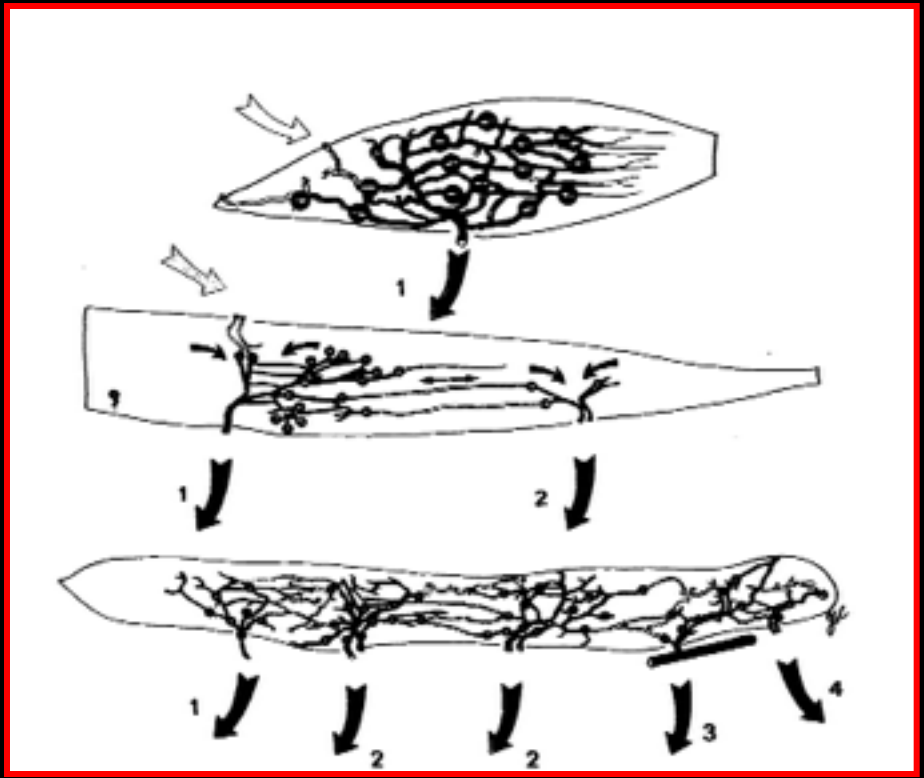

Favorable vs unfavorable mc flaps

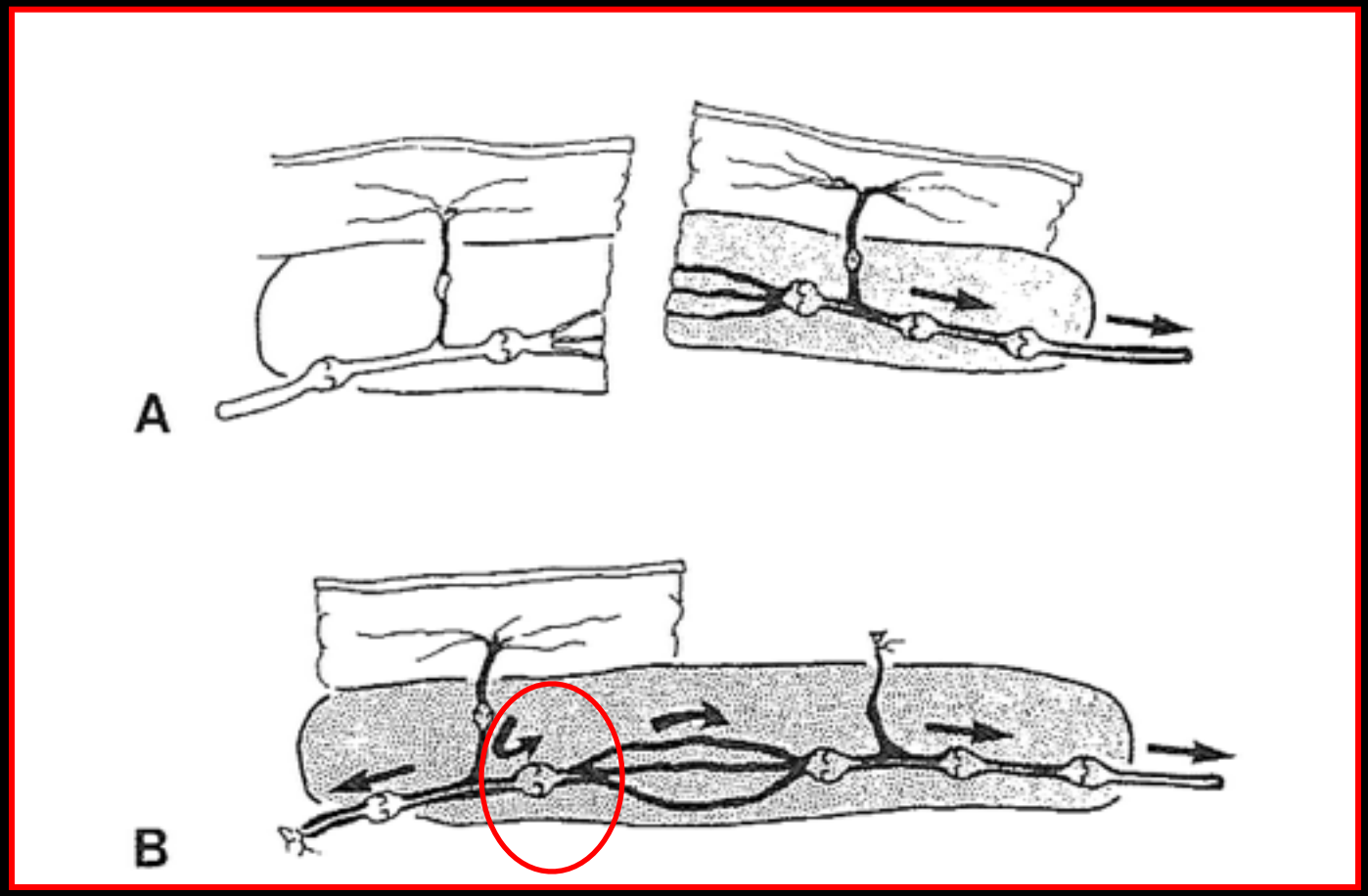

Reverse transposition

- Type V muscles have two arcs of rotation.
- **Standard arc**: dominant vascular pedicle
- **Secondary arc**: secondary pedicles

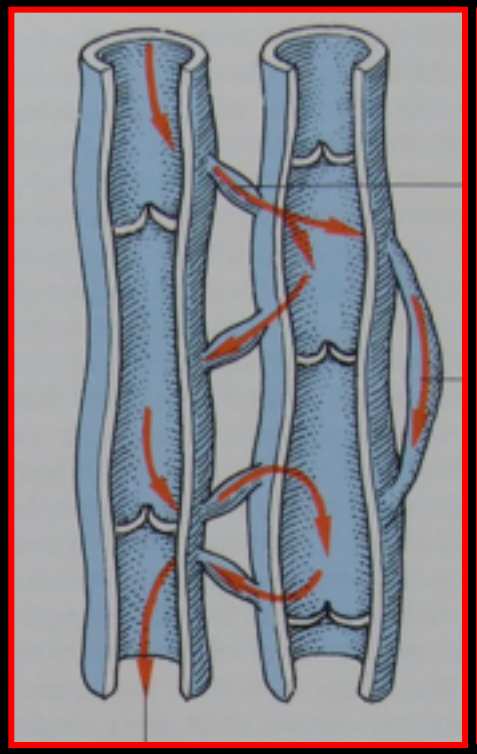

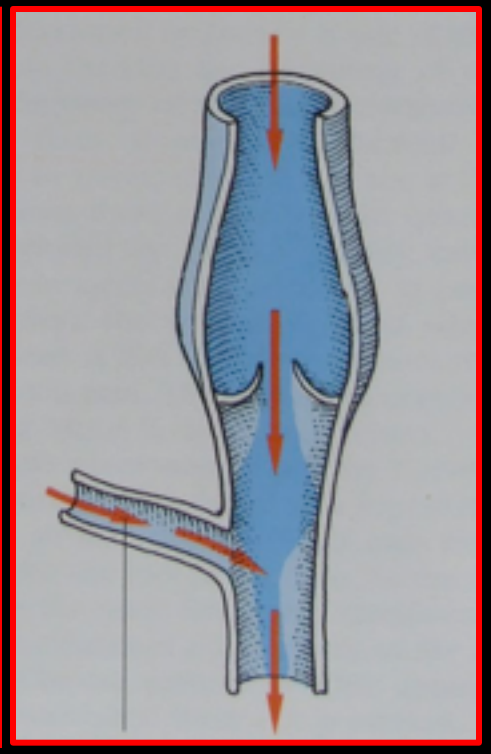

Reverse transposition

Hayashida K, et al.
Case report reconstruction of exposed ilium with reverse turnover latissimus dorsi muscle flap. Eplasty. 2011 Apr 14;11:e17.

Distally based flaps

- **Type II muscle** flaps can be based on the minor pedicles.
- Prior delay can improve the survival and will permit use of the cutaneous territory of the proximal muscle
- It is possible to transpose only a portion of the muscle for small defects based on the minor pedicle.

Flap delay

- Division of selected pedicles

Mathes SJ, et al. Myocutaneous free flap transfer: anatomical and experimental consideration. Plast Reconstr Surg. 62:162, 1978

I. Dilatation of narrow anastomotic vessels linking pedicles supplying adjoining muscle segments

II. changes in the preferential routes of venous drainage within the muscle producing backpressure with regurgitant flow through valves towards the unligated pedicle(s)

Innervation

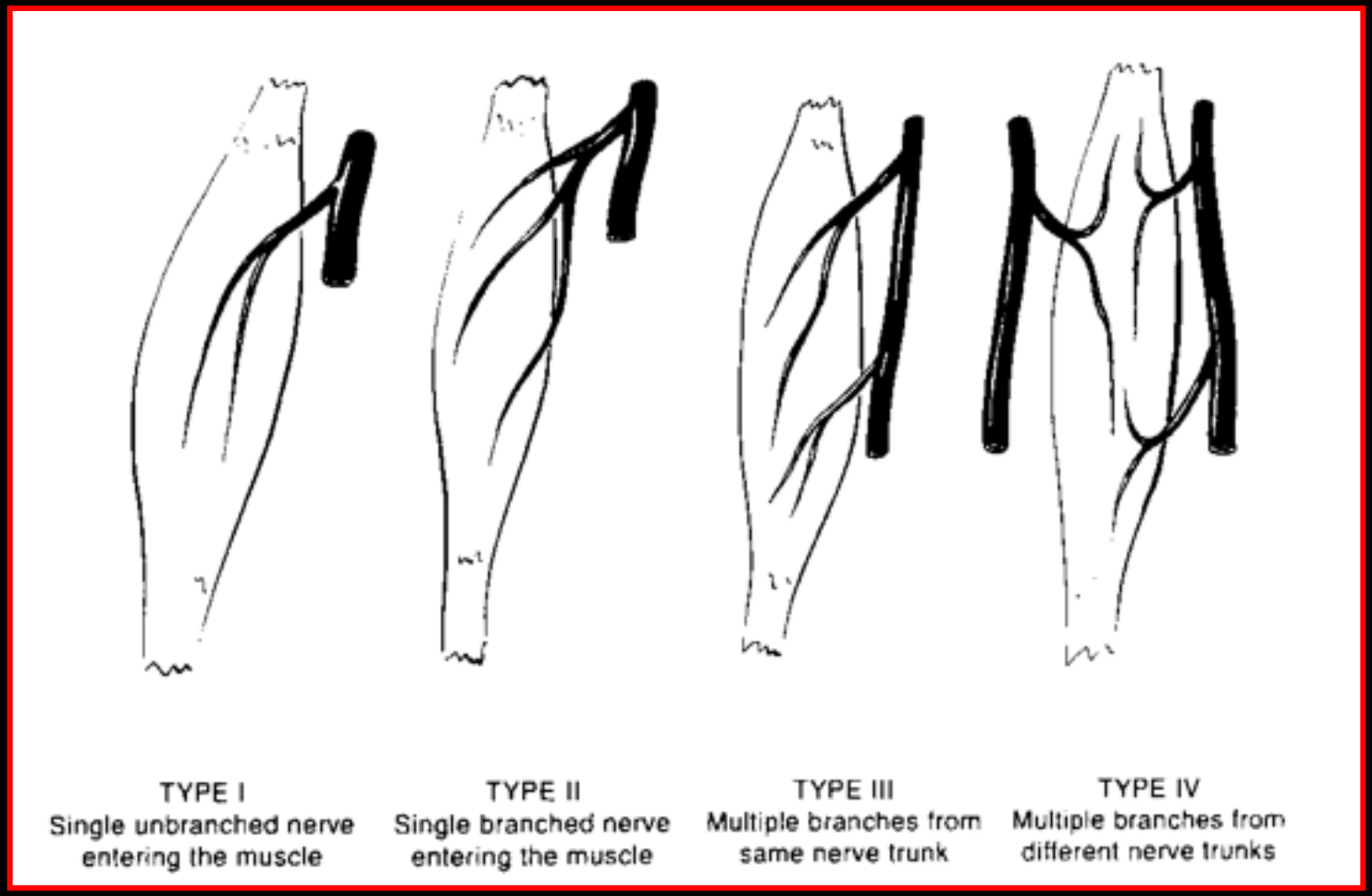

Taylor GI et al. **The neurovascular territories of the skin and muscles: anatomic study and clinical implications** Plast Reconstr Surg 1994 Jul;94(1):1-36.

T

Type I

Single unbranched nerve enters muscle

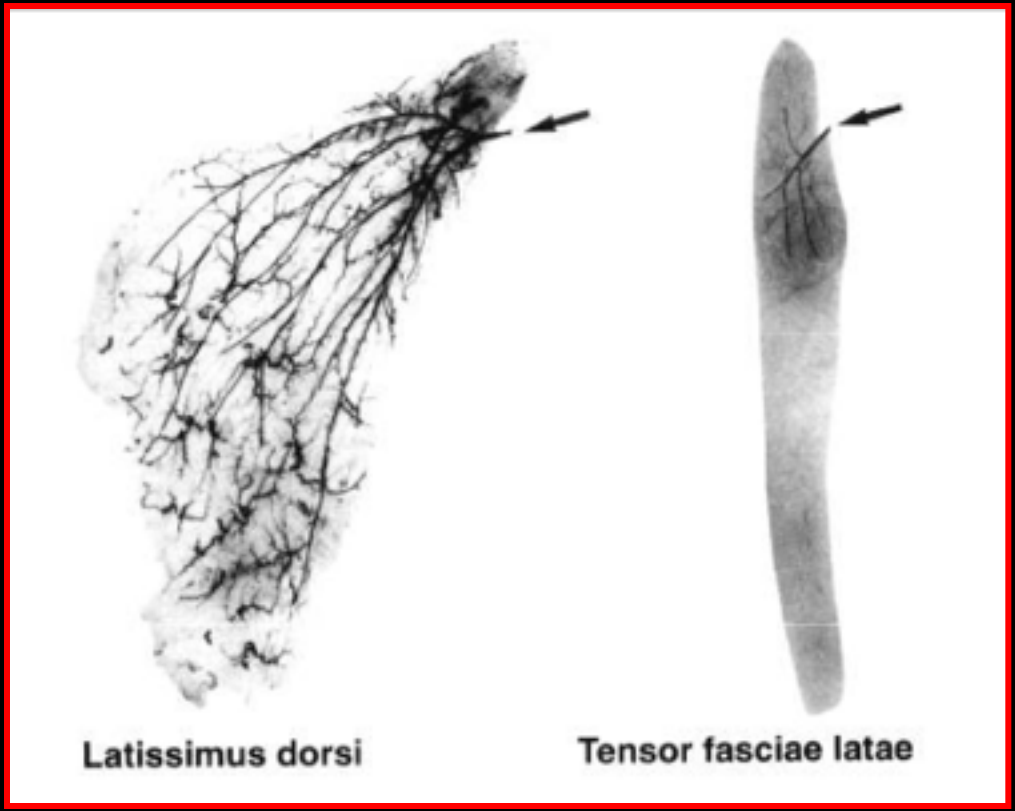

Type II

Single nerve, branches prior to entering

Type III

Multiple branches from same nerve trunk

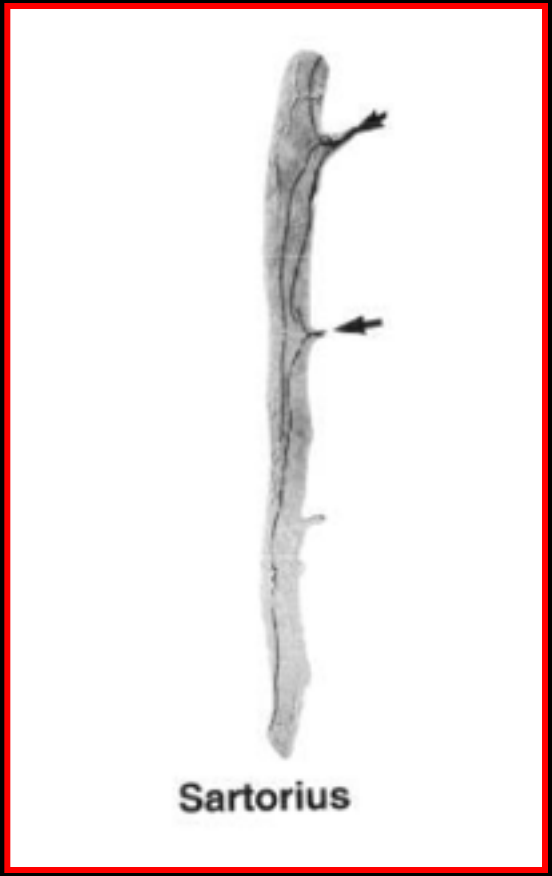

Type IV

Multiple branches from different nerve trunks

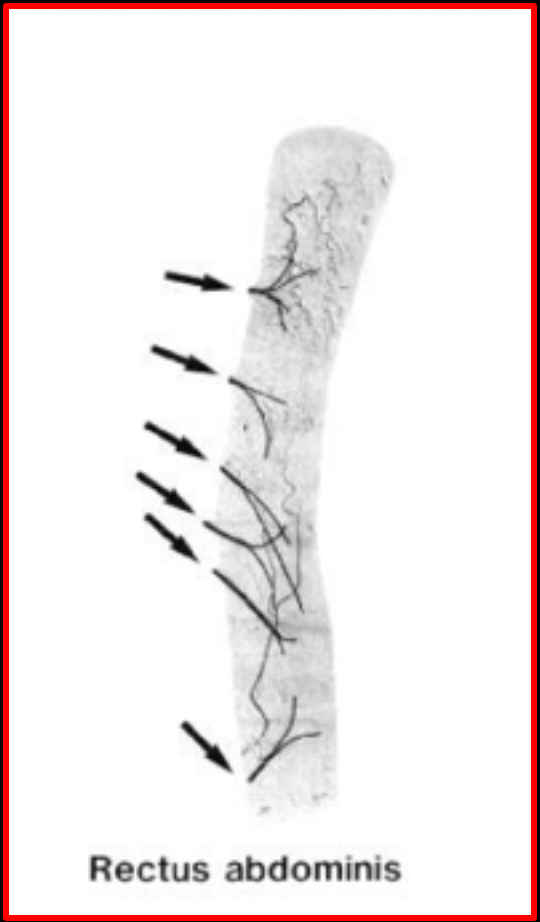

Muscle splitting

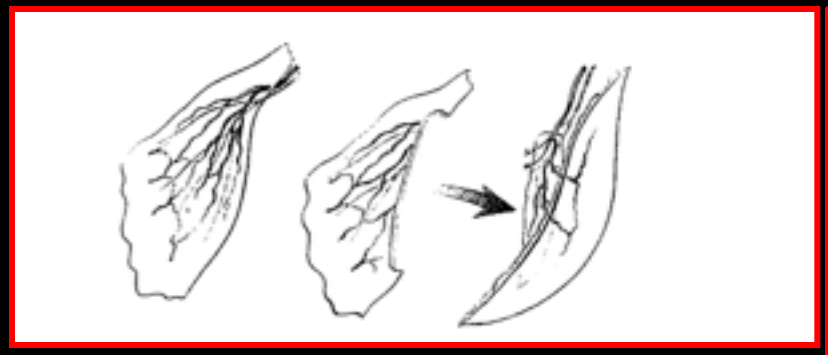

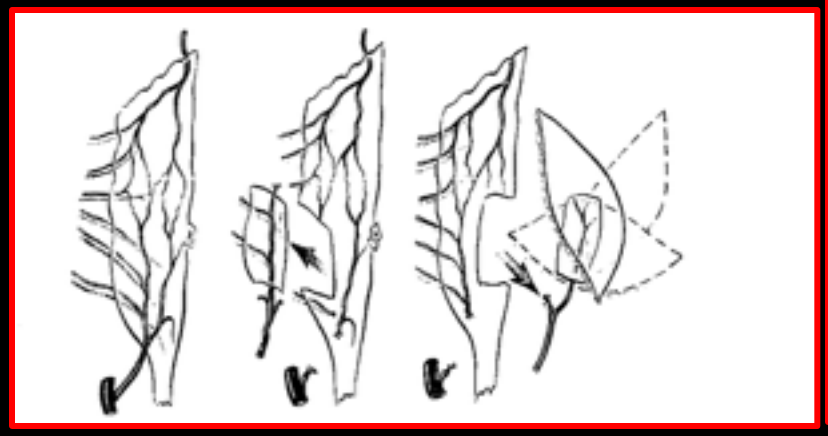

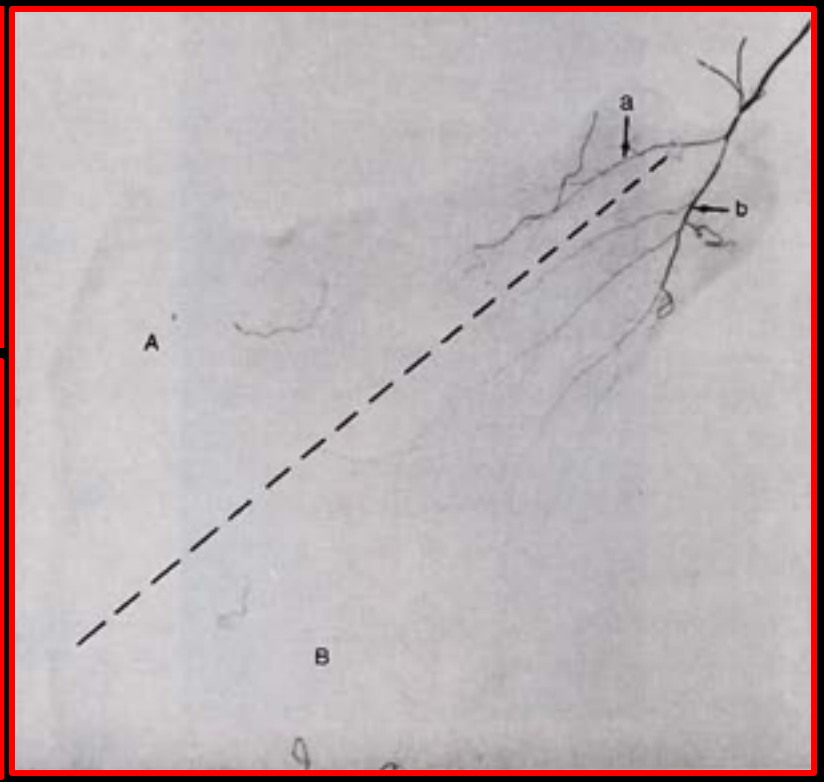

Musculocutaneous Flaps

M-N Classification of Fasciocutaneous flaps

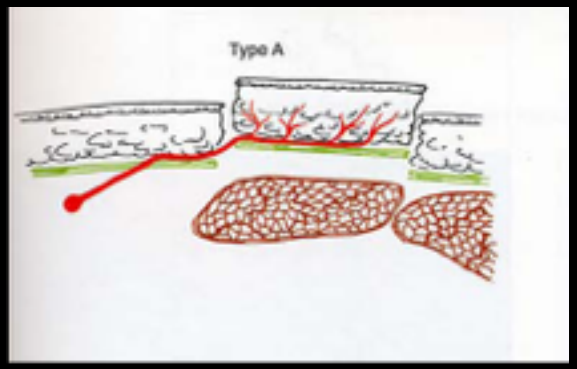

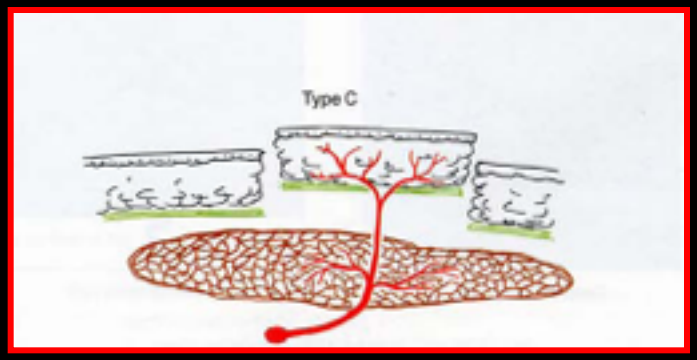

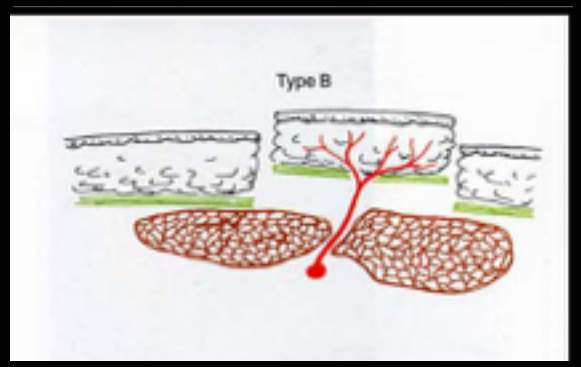

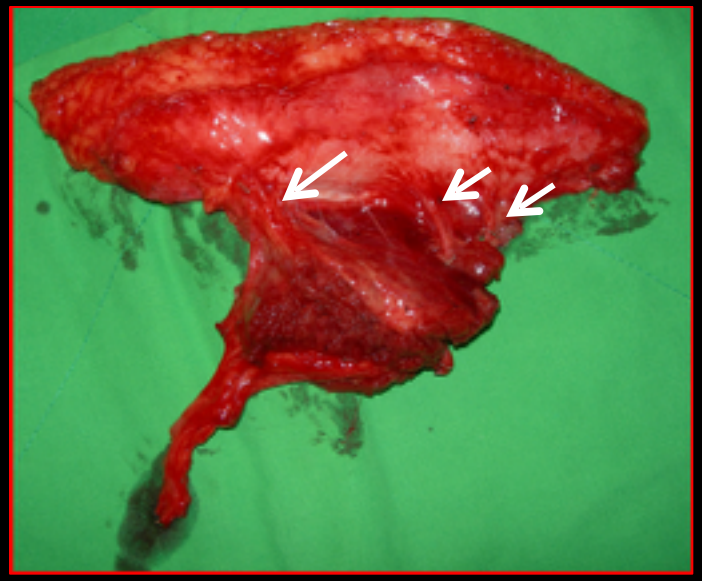

Musculocutaneous flaps

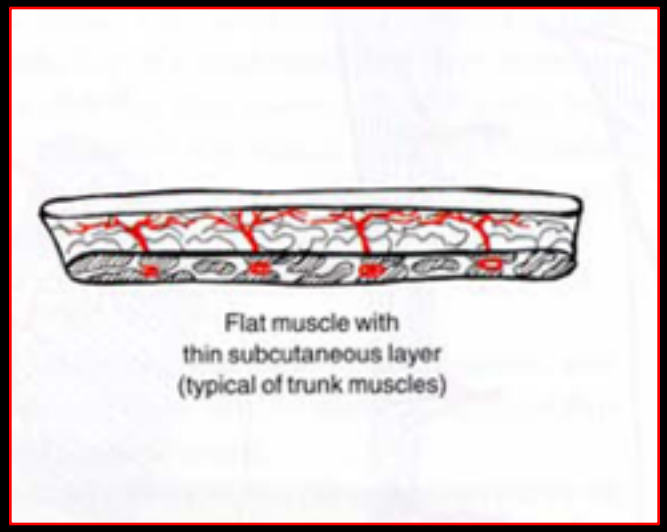

Musculocutaneous flaps

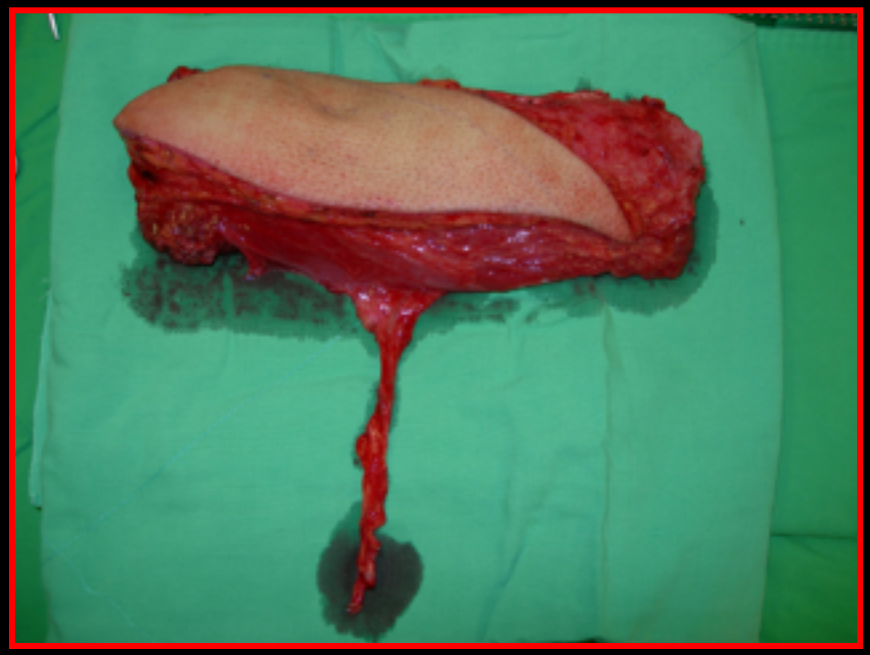

Vascularized bone harvest

- Vascular connections between muscle and periostium of bone
- Free flap
- Transposition flap when vascular connections distal to the point of rotation

Chimeric flaps

- Different tissues on the same pedicle: parascapular, LD, serratus anteriors, scapular angle, ribs

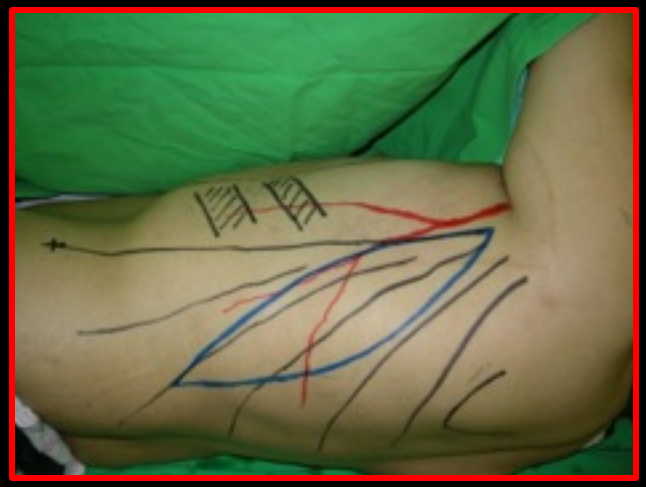

Flap prefabrication

All missing components of a given defect by positioning support lining and coverage tissues in preplanned positions and allowing them to vascularize prior to transfer

Giessler GA et al.The **role** of **fabricated chimeric free flaps** in reconstruction of devastating hand and forearm injuries.
J Reconstr Microsurg. 2011 Nov; 27(9):567-74

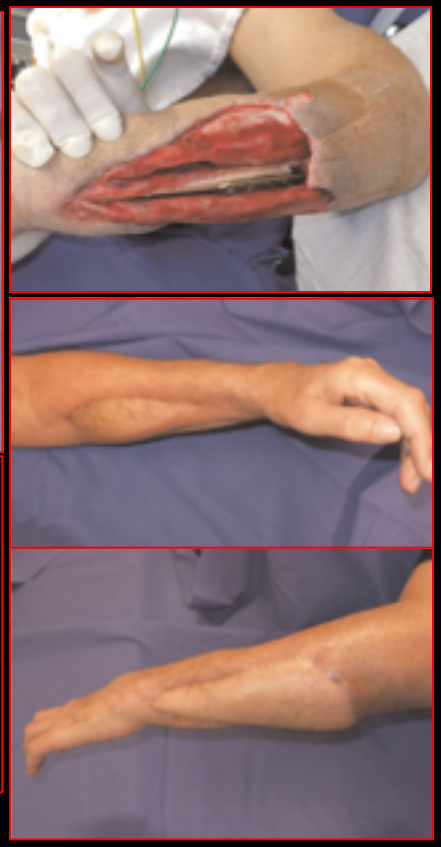

Flap expansion

- Increase in skin island dimensions
- Assists in primary donor-site closure

Nazerani et al. **Extremity resurfacing via an expanded latissimus dorsi musculocutaneus flap for large circumferential defects: the "spiral" reconstruction technique.** Strategies Trauma Limb Reconstr. (2010) 5:115–120

Sensory flaps

- Muscle flaps with intact motor nerves or with reanastomosis of the motor nerve to motor or sensory recipient site appear to retain protective sensation.
- 2/3 of motor nerves are formed by afferent sensory axons.
- 2/3 axons terminate as free endings in the connective tissue surrounding extrafusal and intrafusal muscle fibers. These free endings probably function as nociceptors.
- Decreased atrophy of the sensory innervated muscle flaps

Goldberg JA. Sensory reinnervation of muscle free flaps for foot reconstruction. J Reconstr Microsurg.1994 Jan;10(1):7-9.

Preoperative planning

- Muscle type (Mathes-Nahai)
- Location of the neurovascular hilum/a
- length and thickness
- Lengthen the muscle by excising the deep fascia or incising it at different levels (gastrocnemius)
- Cut the motor nerve to avoid contraction and pain

Pedicled flaps

Upper extremity

Flap transposition

- Point of rotation (pivot): point of entrance of the pedicle
- **Standard arch of rotation**: length of the vascular pedicle + flap length distal to the pivot
- Pivot types I, II, III, V: one end or proximal third
- Type III: the whole m may not always survive on one of dominant pedicle
- Type IV: only the proximal third transposed
- Type V has 2 arc of rotation

Arc of rotation

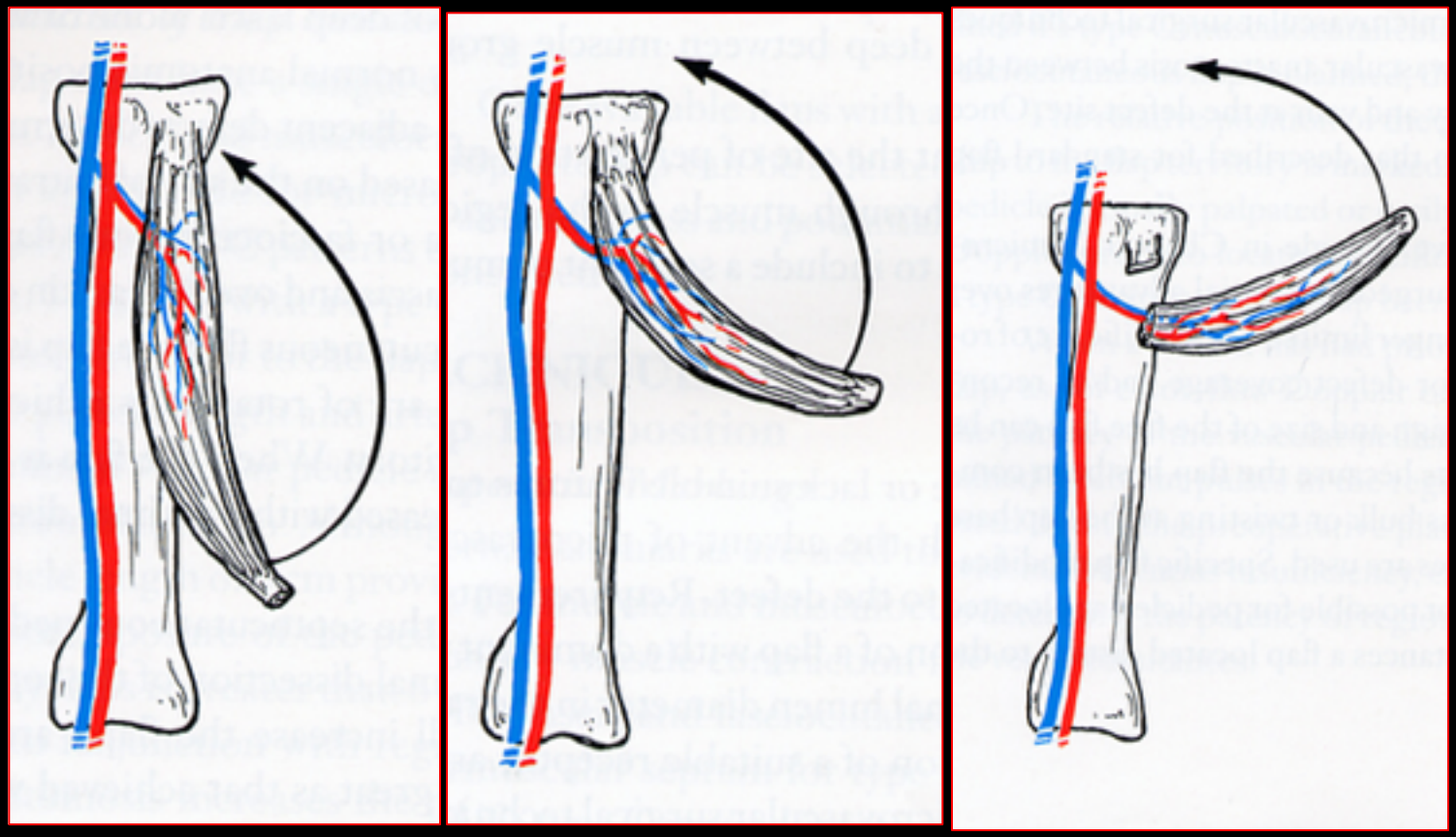

Standard arc **Extended arc**

Shoulder and upper arm

- LD
- Serratus anterior
- Pectoralis minor

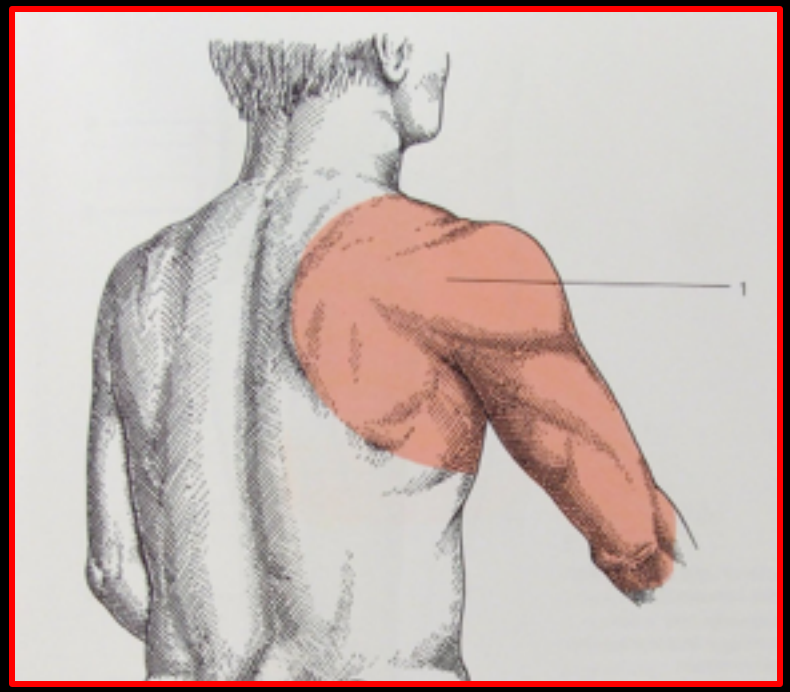

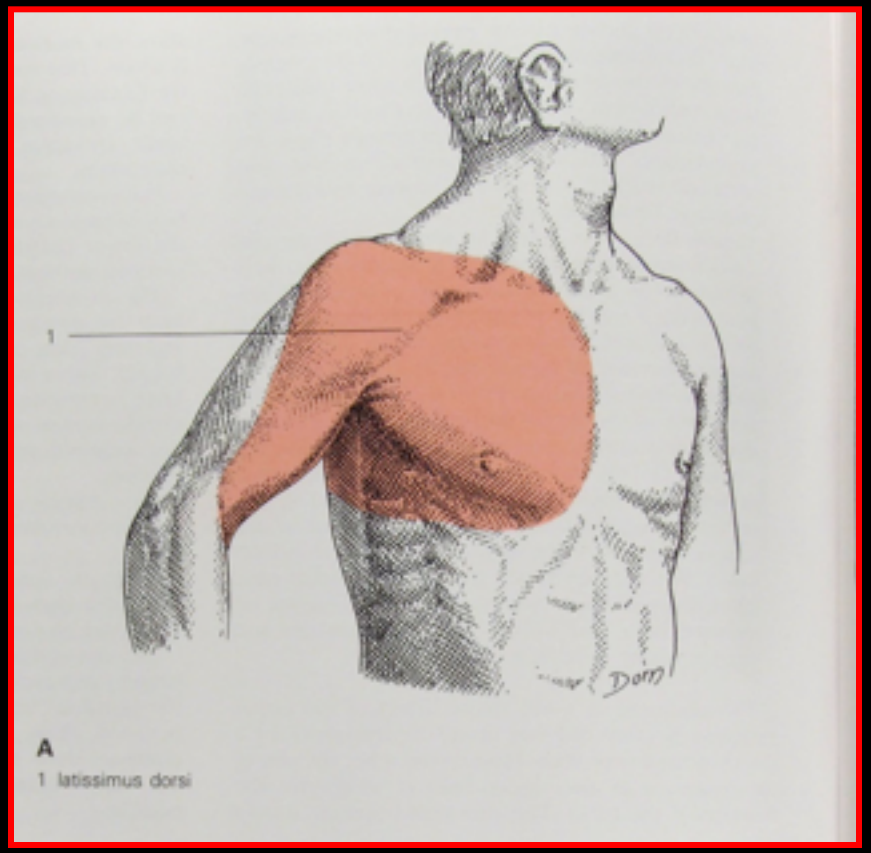

Forearm

Brachioradialis (II)
Anconeus (I)

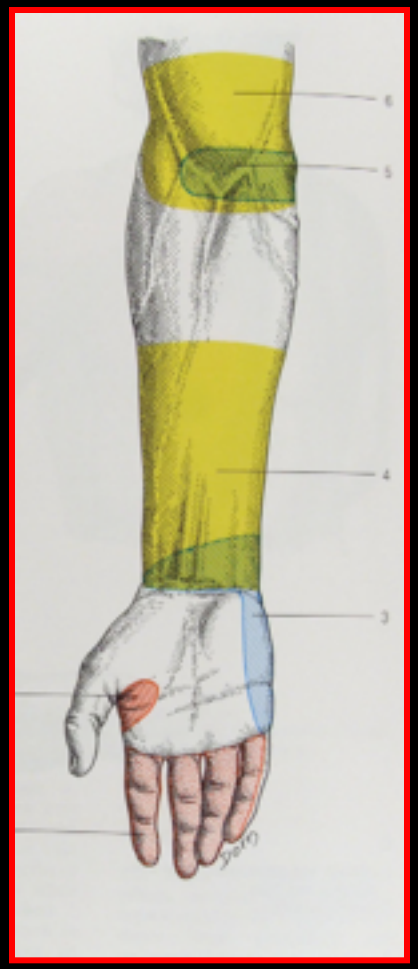

Brachioradialis muscle flap: clinical anatomy and use in soft-tissue reconstruction of the elbow. Ann Plast Surg.1995 Jul; 35(1):70-6. Rohrich RJ et al

Outcome of local anconeus flap transfer to cover soft tissue defects over the posterior aspect of the elbow. Elhassen et J Shoulder Elbow Surg (2011) 20, 807-812 al.

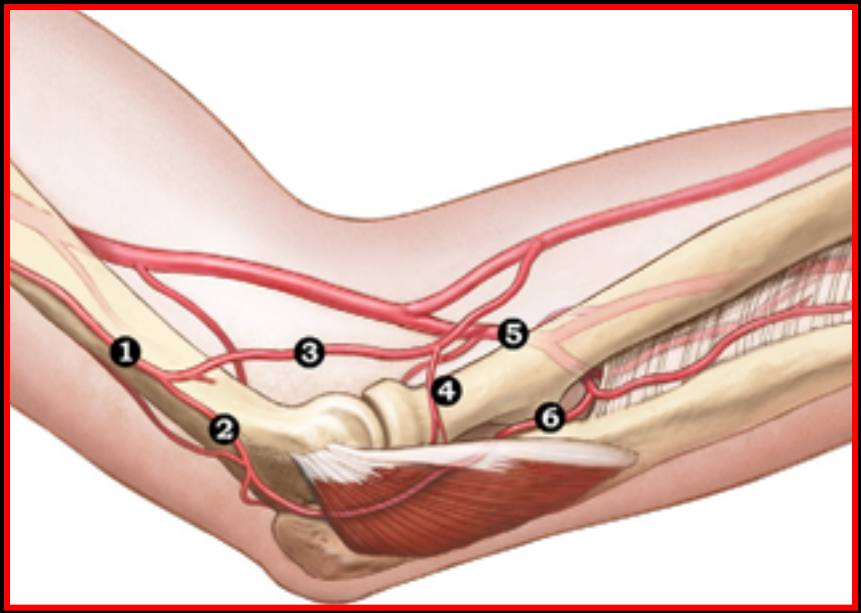

1- Profunda brachii artery;
2- medial collateral artery; 3- radial collateral artery; 4- posterior
branch of the radial collateral artery; 5- ulnar collateral artery;
6- the recurrent posterior interosseous artery.

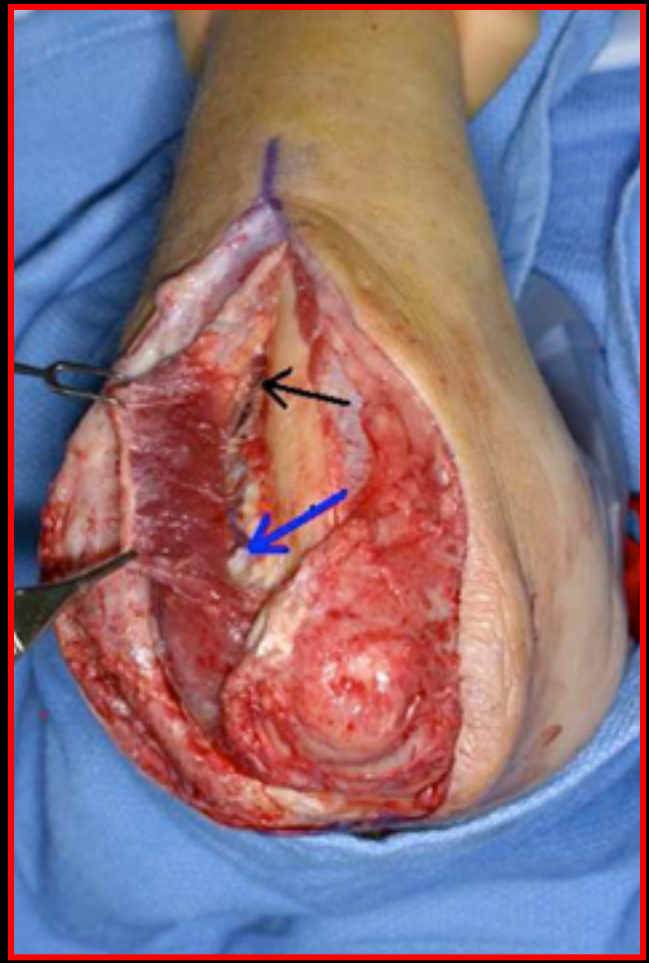

Hand

- Abductor Digiti Minimi (I)

A, incision for ADM harvest. B, incision for fixation of transfer of ADM. C, ADM exposure. D, ADM mobilized. E, ADM 2 insertions (small finger and extensor retinaculum). F, ADM transfer. G, ADM transfer with Palmaris longus graft.

De Roode, C et al . **Abductor Digit Minimi Opponensplasty: Technique, Modifications, and Measurement of Opposition.** Techniques in Hand & Upper Extremity Surgery. 14(1):51-53, March 2010.

Free flaps

1. limited regional options for muscle rotation
2. the volume of the defect is larger than local tissues can reconstruct.
3. Functional deficits from using the regional muscle supply may limit the outcome
4. Infection or prosthetic coverage

Complex wounds

- Osteomyelitis
- Vascular insufficiency
- Chronic irradiation wound
- Infected exposed prosthesis

Muscle vs Fasciocutaneous flaps

- Musculocutaneous flaps vs random fasciocutameous flaps
- Both muscle flaps and nonmuscle flaps are effective in providing coverage for bone defects with chronic osteomyelitis following adequate debridement.

-Mathes SJ, et al.. Use of the muscle flap in chronic osteomyelitis: experimental and clinical correlation. Plast. Reconstr. Surg. 69: 5, 1982.
-Salgado CJ. Et al Muscle versus nonmuscle flaps in the reconstruction of chronic osteomyelitis defects. Plast Reconstr Surg. 2006 Nov;118(6):1401-11.
-Hong JP et al. **The use of anterolateral thigh perforator flaps in chronic osteomyelitis of the lower extremity.** Plast Reconstr Surg. 2005 Jan;115(1):142-7.

Functional muscle transfer

Functional muscle transfer

- 1970 Tamai: functional rectus femoris transfer in dogs
- 1976 Harii: gracilis for facial reanimation
- 1976 Sixth People Hospital: lateral pectoralis major for forearm flexors in Volkman
- 1978 Manktelow: gracilis and pectoralis for active finger flexion

Loss of functioning muscle unit

Major loss of skeletal muscle with significant functional deficit that cannot be reconstructed by simpler procedure.

- Direct trauma, burns
- Tumor resection
- Volkmann's ischemic contracture
- BPP

Criteria

- Single unit replacement must make a difference
- Adequate antagonist muscle function
- Suitable bed for gliding, distal gliding tendons
- Mobile joints, stable bones
- Sensate distal extremity
- Effective motor nerve
- Cooperative patient

FMT in upper extremity

- Long finger flexor function
- Long finger extensor funtion
- Biceps reconstruction
- Triceps reconstruction
- Deltoid reconstruction

Donor muscle

- Fibre Length
- Fibre configuration
- Excursion
- Vessel and nerve size / position
- Fascia / tendon for insertion
- Ischemia time

Fiber length

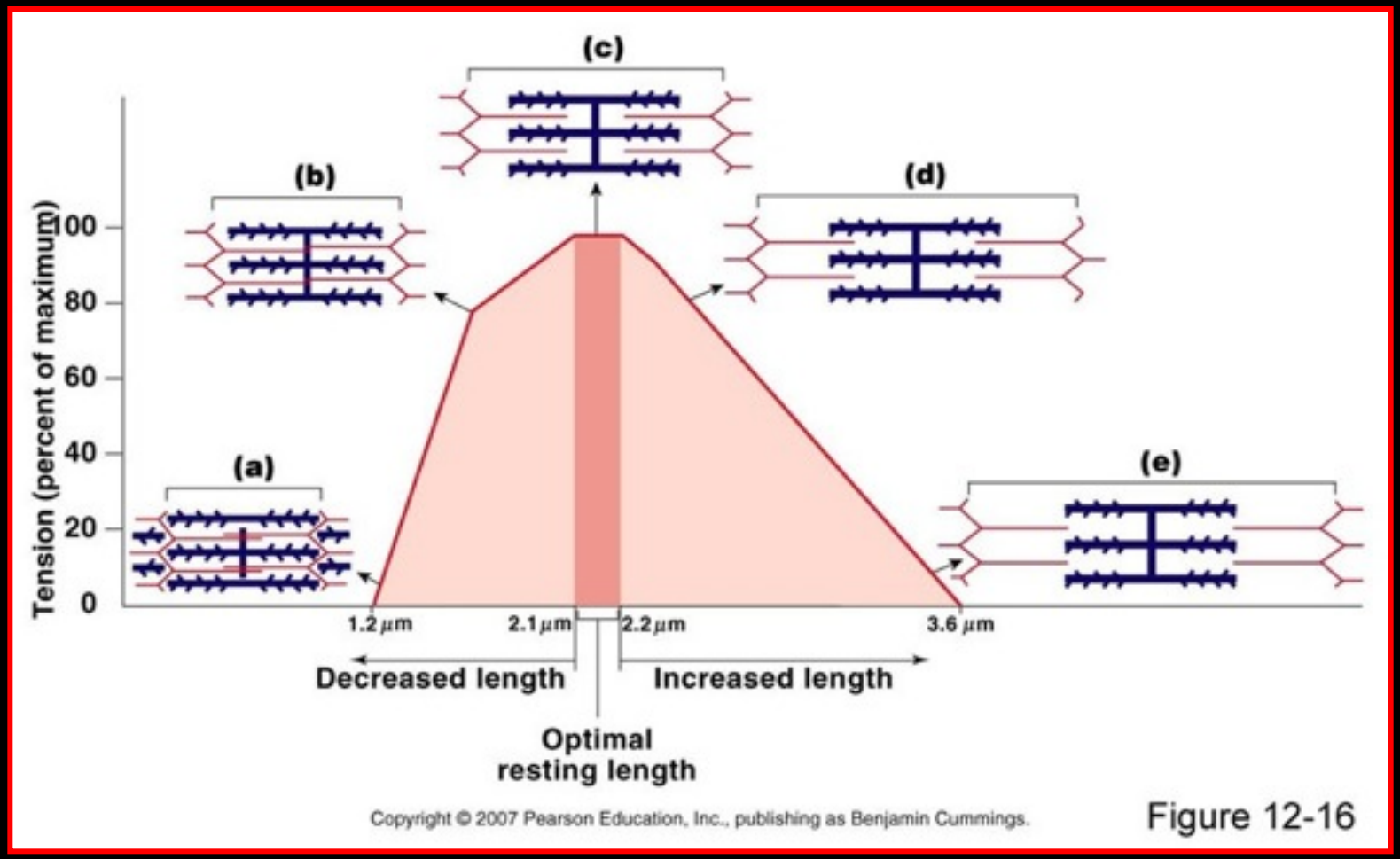

Figure 12-16

Pedicled LD

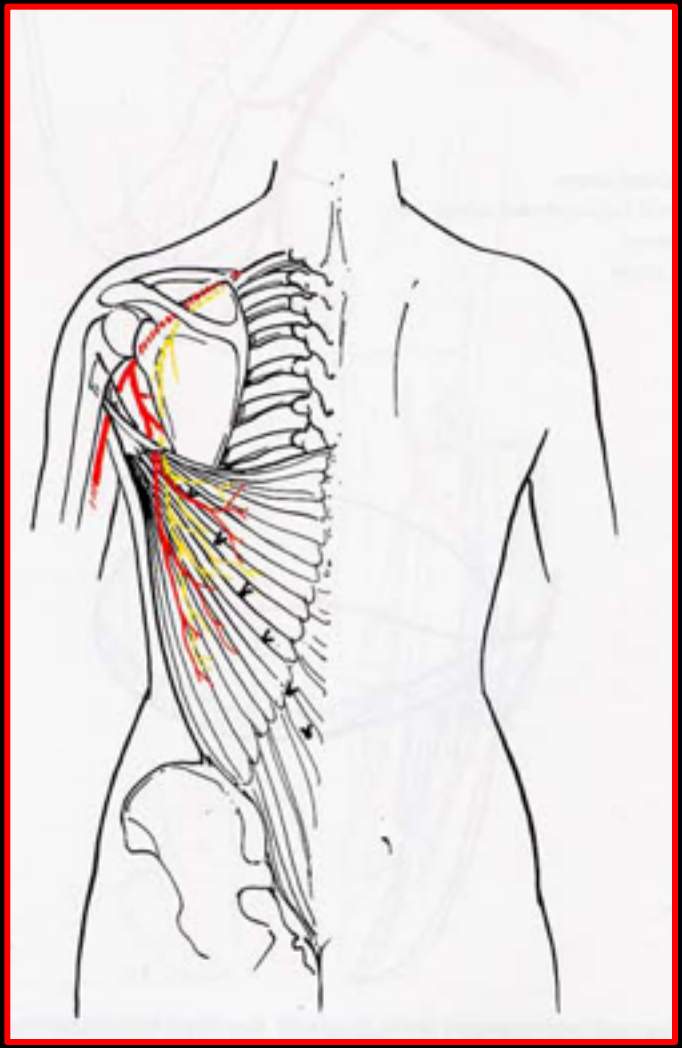

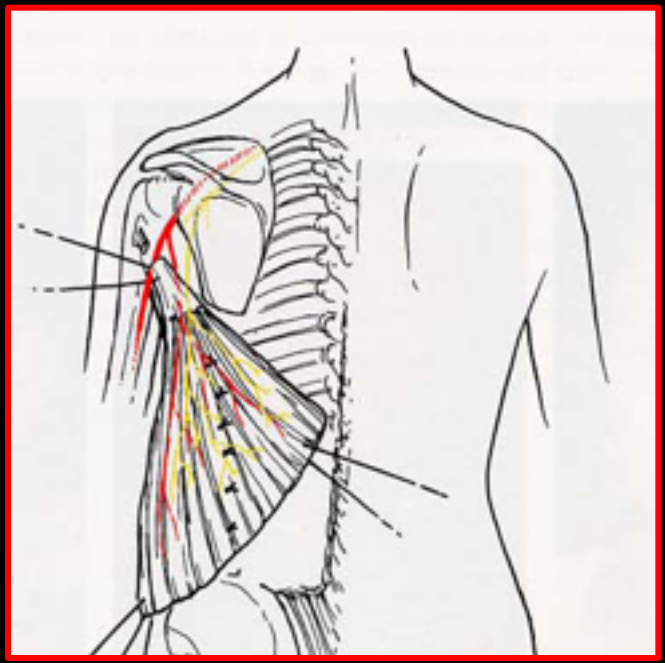

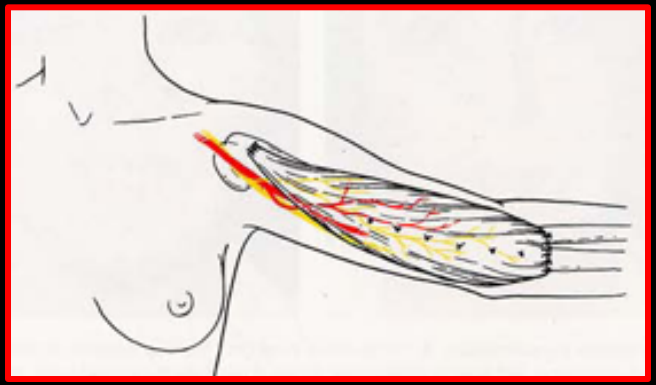

Fiber configuration

- **Strap muscle**: fibers are parallel to the long axis of the muscle

  shortening: muscle length

  max force: cross section
- **Pennate muscle**: shorter muscle fiber units attached to central/lateral tendon.

  <shortening; >power
- Select strap m with large cross sectional area

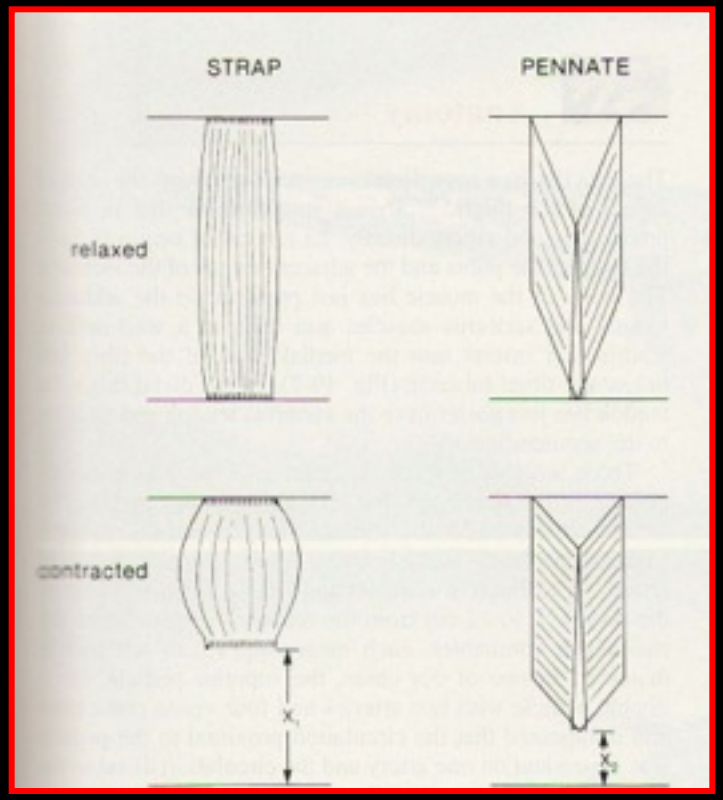

Donor Muscle

- **Gracilis**
- **Latissimus dorsi**
- Pectoralis major
- Rectus femoris
- Tensor fascia lata

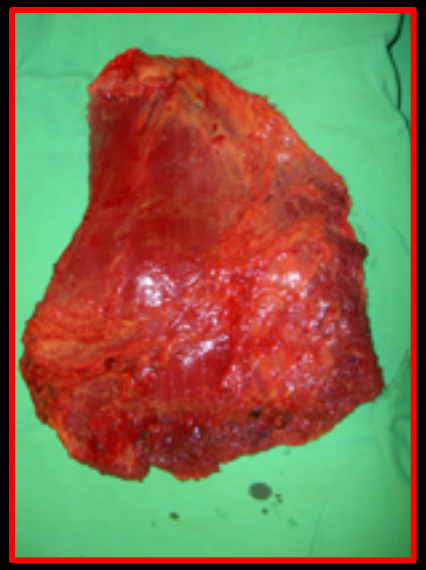

Donor Nerves

- **Finger long flexors**: AIN, median nerve (FDS), ulnar nerve (FDP)
- **Finger long extensors**: radial nerve, PIN
- **Biceps**: motor musculocutaneous nerve
- **Deltoid**: motor axillary
- **Triceps**: proximal radial nerve
- BPP: IC, cC7, spinal accessory, C5, C6

Healty motor nerve equal cross sectional area

Pretransfer abnormalities

- Nerve loss
- Joint contractures
- Tendon adhesions

Insertion and origin

Insertion tendon	Origin
• Side to side repair of FDP/ EDC • Side to side repair of FPL/EPL • EPL rerouting: extension +abduction • Split muscle and innervate with different motor: independent finger and thumb	• Medial epicondyle (flexors) • Lateral epicondyle (extensors)

24 yo M

- Complete loss of the extensor compartment of the forearm
- Exposure of the dorsal aspect of radial and ulnar bones.
- The posterior interosseous nerve was interrupted 3 cm from its origin.

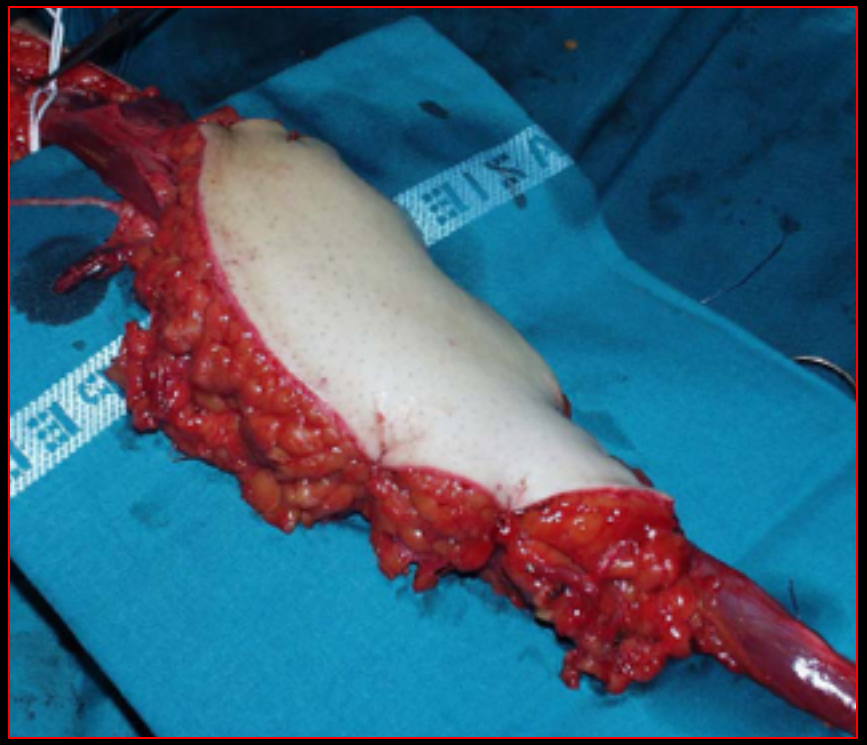

Post operative management

- Finger flexors:
- Passive finger and wrist stretching at 3 weeks
- Gradual resisted grip exercises
- For 1 year after development of useful ROM
- Finger extensors:
- Wrist splinted in extension for 10-14 days
- Passive and active wrist, finger and thumb exericises
- Exercise against resistance when useful range of finger extension (6 months)

Outcomes

- Tip to palmar crease 0.5-4cm
- Grip strength 38.1% (14-81%)
- Pinch strength 37.8% (0-70%)
- Severity of pretransfer upper extremity injury
- Absence of intact intrinsic function
- Absence of good supination and pronation

Manktelow RJ. **Functioning free muscle transplantation.** J Hand Surg Am. 1984 Jan;9A(1):32-9.

Biceps Reconstruction

- Lack of elbow flexion
- Local transfers not possible (LD, pec >)
- Donor nerves: musculocutaneous, intercostal (BPP: 2-4th).
- Contraindications to IC nerves: phrenic nerve palsy, Brown Sequard Sdr
- Awake nerve stimulation: sensory (discomfort in the region of the sensory innervation), motor (deep discomfort localized in the muscle belly)

Biceps reconstruction

- Origin: acromion and clavicle
- Insertion: remnant of biceps tendon with elbow and shoulder in full extension
- Post op: elbow in flexion (3weeks) , active and passive stretching. Transfer activated by breathing

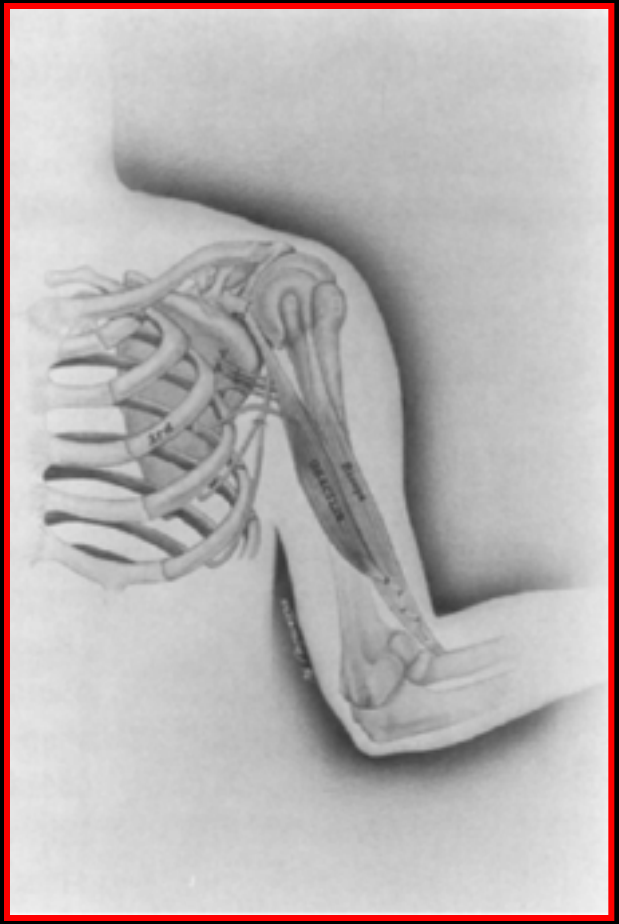

Chuang DCC. Results of Functioning Free Muscle Transplantation for Elbow Flexion. J Hand Surg 1996;21A:1071-1077.

Biceps reconstruction: outcome

- full active flexion (M4), load 5 Kg
- M4 in 78% of patients following transfer of 3 intercostal nerves with recovery in 2 years. Using the spinal accessory nerve, strength of M2+ (interposition nerve grafts)
- Gracilis->gracilis+adductor longus->RF, VL, LD
- LD stronger than gracilis and rectus femoris (IC).

Chuang DCC. Results of Functioning Free Muscle Transplantation for Elbow Flexion. J Hand Surg 1996;21A:1071-1077.
Terzis JK. Free Muscle Transfer in Posttraumatic Plexopathies Part II: The Elbow. HAND (2010) 5:160–170

Biceps reconstruction: outcome

Terzis JK. Free Muscle Transfer in Posttraumatic Plexopathies Part II: The Elbow. HAND (2010) 5:160–170

Triceps Reconstruction

- **Origin**: lateral aspect of scapula (glenoid fossa)
- **Insertion**: triceps tendon, olecranon
- **Nerve**: radial nerve, IC, cC7 posterior division,
- cervical plexus, and distal spinal accessory nerve
- **Muscle**: LD, gracilis
- **Postop**: shoulder flexion and elbow extension
- **Outcome**: LD stronger (M3), gravity aid

Terzis JK. Free Muscle Transfer in Posttraumatic Plexopathies Part II: The Elbow. HAND (2010) 5:160–170

Triceps Reconstruction

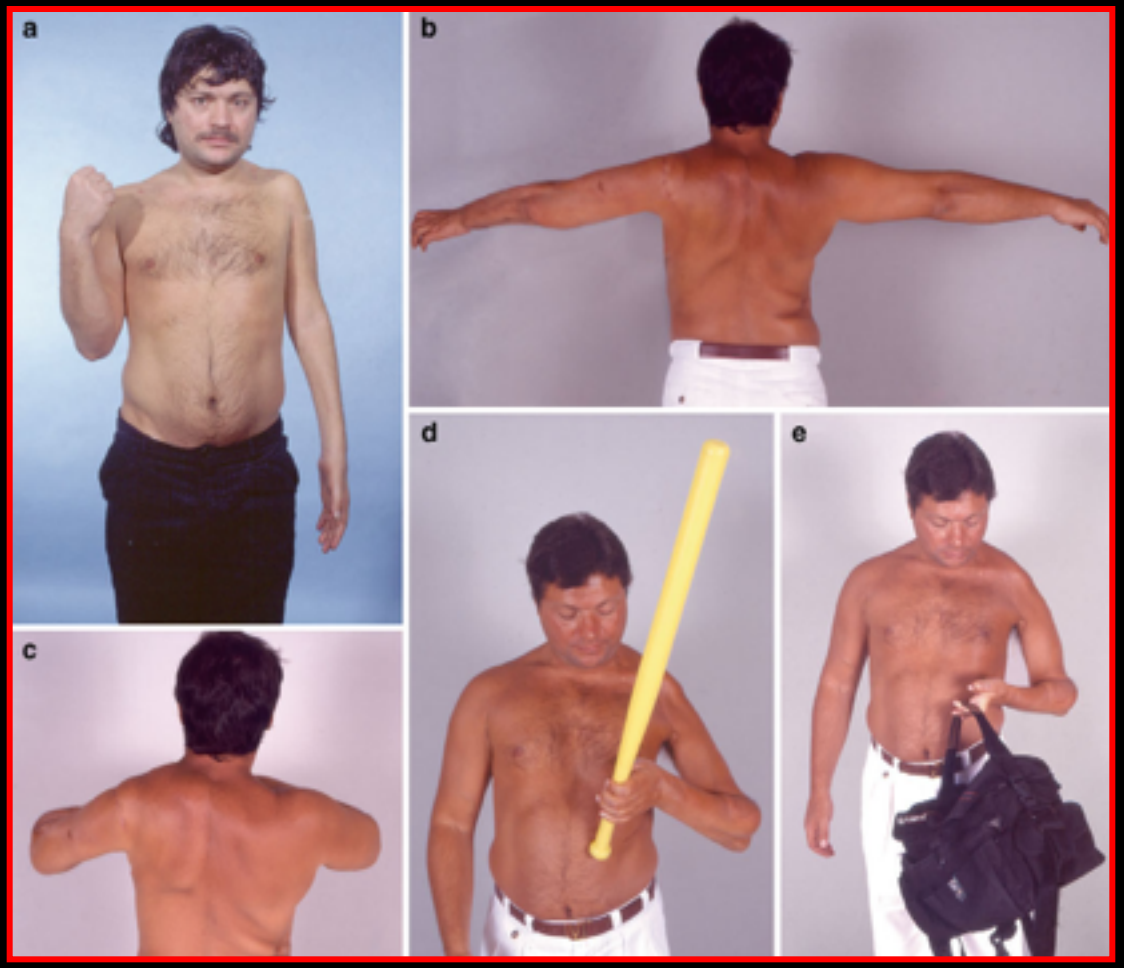

Terzis JK. Free Muscle Transfer in Posttraumatic Plexopathies Part II: The Elbow. HAND (2010) 5:160–170

Deltoid reconstruction

- Shoulder Flexion and abduction
- Complete loss of deltoid: supraspinatus, pec >, biceps and coracobrachialis
- Muscles: gracilis and adductor longus, LD
- Nerve: IC, cC7 root , distal spinal accessory nerve
- Origin: acromion and distal clavicle- nucal line
- Insertion: deltoid
- Postop: shoulder 90°abduction and elbow flexed. ESTIM. Splint removed at 3 months

Terzis JK. Free Muscle Transfer in Posttraumatic Plexopathies *Part 1: The Shoulder. Ann Plast Surg 2010;65: 312–317*

Outcome

- LD: The mean muscle grade postoperatively was 3.25. The mean degree of shoulder abduction was 40°.

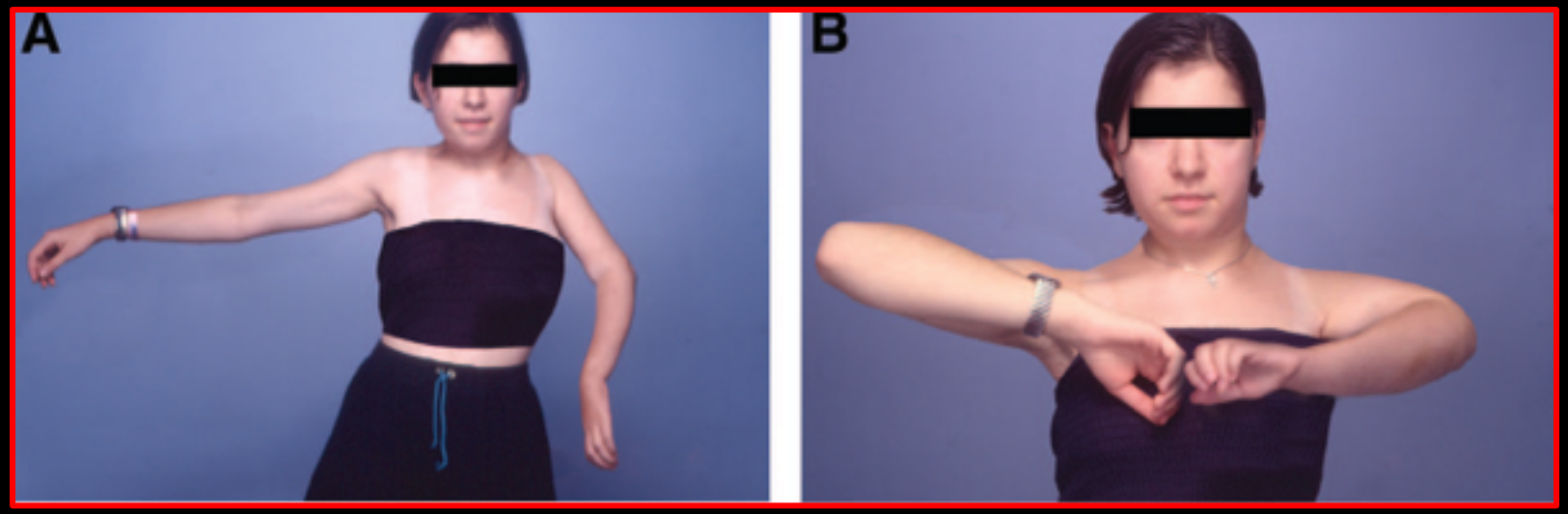

Terzis JK. Free Muscle Transfer in Posttraumatic Plexopathies *Part 1: The Shoulder. Ann Plast Surg 2010;65: 312–317*

The Reconstructive Elevator

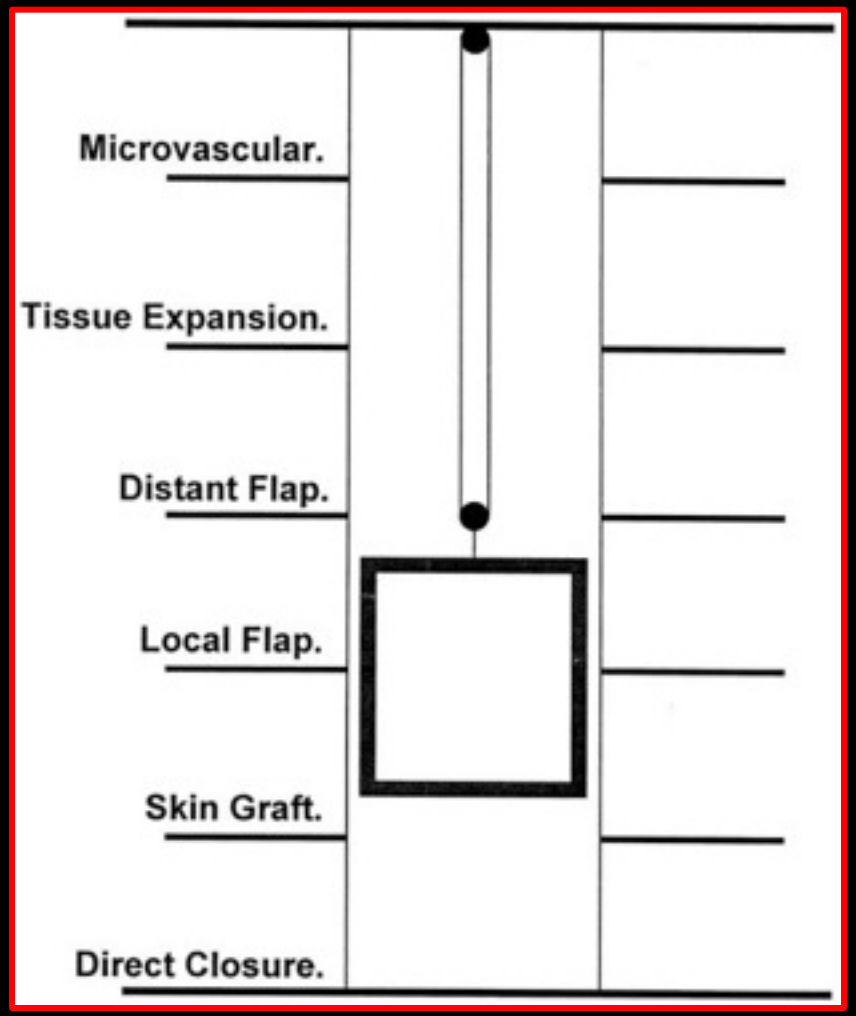

Bennett N et al. **Why climb a ladder when you can take the elevator?** Plast Reconstr Surg. 2000 May;105(6):2266.

Editorial

From the Reconstructive Ladder to the Reconstructive Elevator

"In the era of form and function simplest is not always the best."

Lawrence J Gottleib

Plast Reconstr Surg.1994 Jun;93(7):1503-4.

British Medical Research Council Scale

- M0: No contraction
- M1: perceptible contraction in proximal muscles
- M2: perceptible contraction in both proximal and distal muscles
- M3: all important muscles able to work against resistance
- M4: All synergistic and independent movements possible
- M5: complete recovery