Tendon Transfer and Combined Nerve Palsy

Biomechanics of Tendon Transfers

- Positive Factors
  - Balance
  - Strength
  - Mobility
- Negative Factors
  - Stiffness
  - Deformity
  - Disuse

Balance

"In the management of paralysis, balance is more important than strength."

Brand, 1988

Balance

- Must redistribute muscle power that remains in forearm and hand
- Does not mean equal power on each side of a joint
  - Normal hand
    - Digital extensors weaker than flexors
      - Do not contract against each other
      - Work in harmony (flexors relax as extensors fire)
    - Wrist extensors must be strong enough to balance finger flexors
      - Contract simultaneously against each other on opposite sides of wrist joint
      - Must produce equal torque on each side of wrist joint to provide stability for distal activity
- Synergism

Synergism

- Active Synergism
  - Occurs when muscles have to contract together in order to augment the effectiveness of each muscle
  - Needed when a sequence of joints must be controlled
- Sequential synergism
  - Active contraction of one muscle stretches an opposing muscle
  - Energy in stretched position released when opposing muscle contracts

Synergism

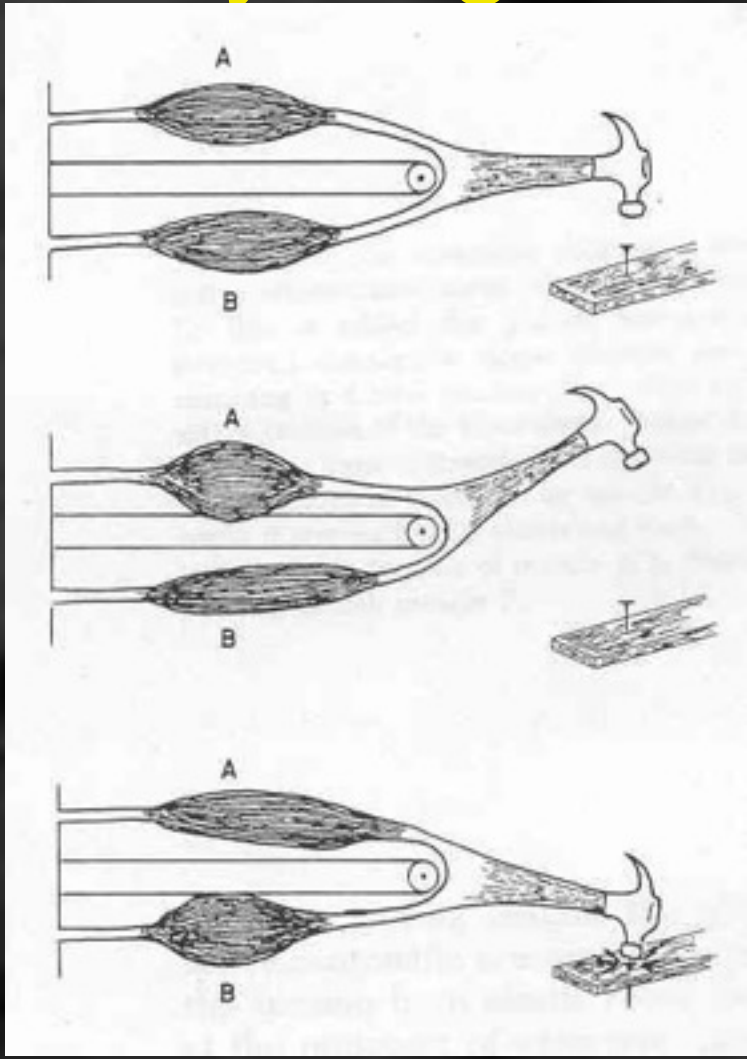

(Clinical Mecanics of the Hand, 1985)

Blix Curve

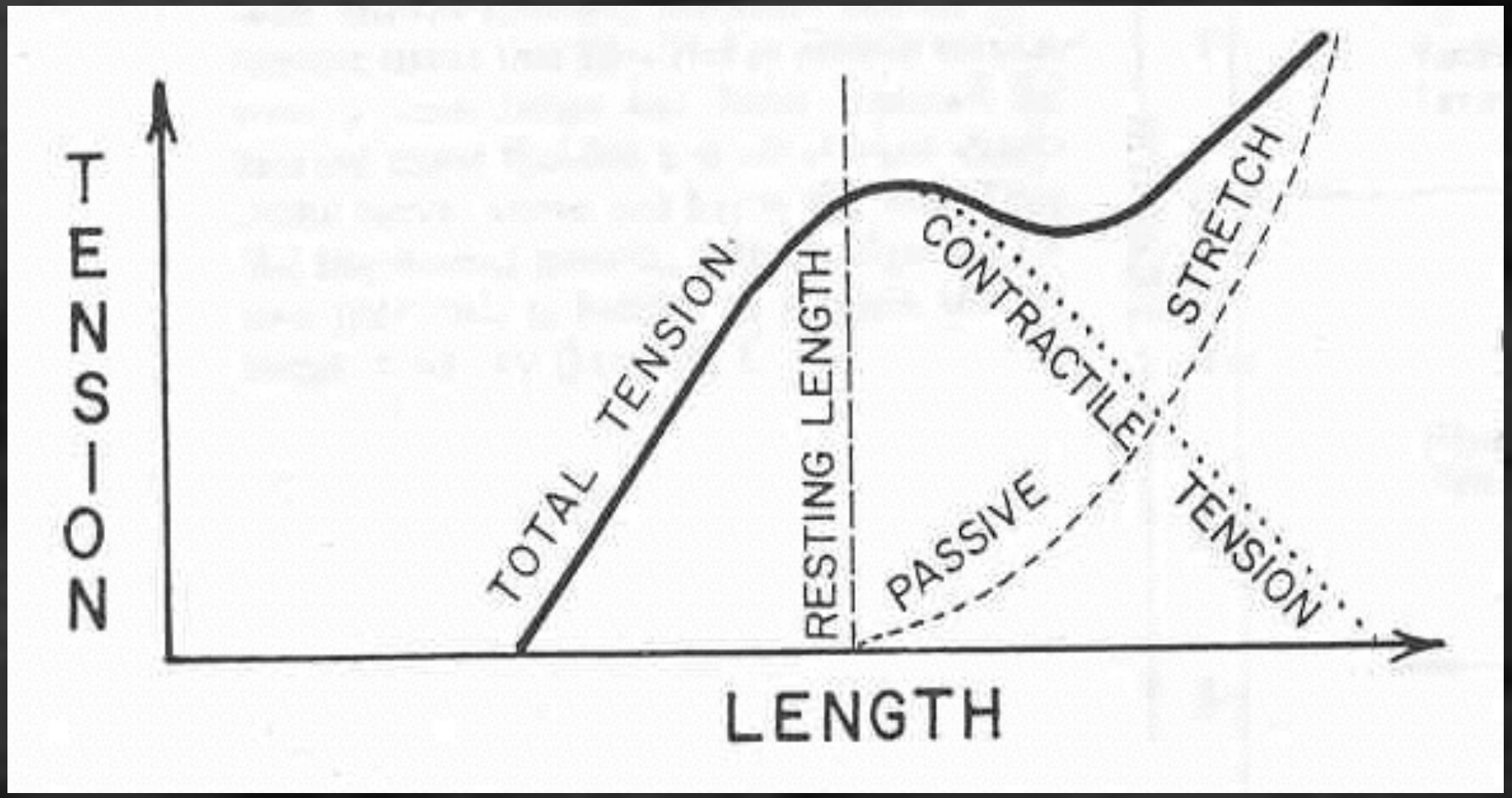

(Skand Arch Physiol, 1891)

Synergism

- When limb is rested with some muscles slack and some stretched
  - Slack muscles absorb sarcomere units
  - Stretched muscles add sarcomere units
  - Ultimately, all fibers reach their original resting tension
  - True of other tissues as well
    - Joint capsule
    - Ligaments
    - Skin

(Hand Clinics, 1988)

Synergism

- Surgeon can not alter the final resting tension of a muscle fiber
- If pulled to stretched position before new insertion, extra tension is only temporary
- High tension stimulates electromyographic signals that may produce discomfort
- Helps patient identify muscle and its new action

(Hand Clinics, 1988)

Planning

- Each muscle needs an opposing muscle to achieve its own best output
- Must consider this balance when planning transfers
- Do not just list “paralyzed” muscles and “available” muscles

Planning

- Factors to consider:
  - Patient needs
  - Available muscles for transfer
    - Unparalyzed
    - Least deficit
    - Strength
    - Excursion

Strength vs. Excursion

- Stength
  - Potential for creating tension
  - Lack of strength can be compensated for with therapy
- Excursion
  - Distance through which tension can be maintained
  - If too short, can not lengthen with therapy
  - Can compensate (extrafunctional excursion) by flexing one joint in series while extending others

Planning

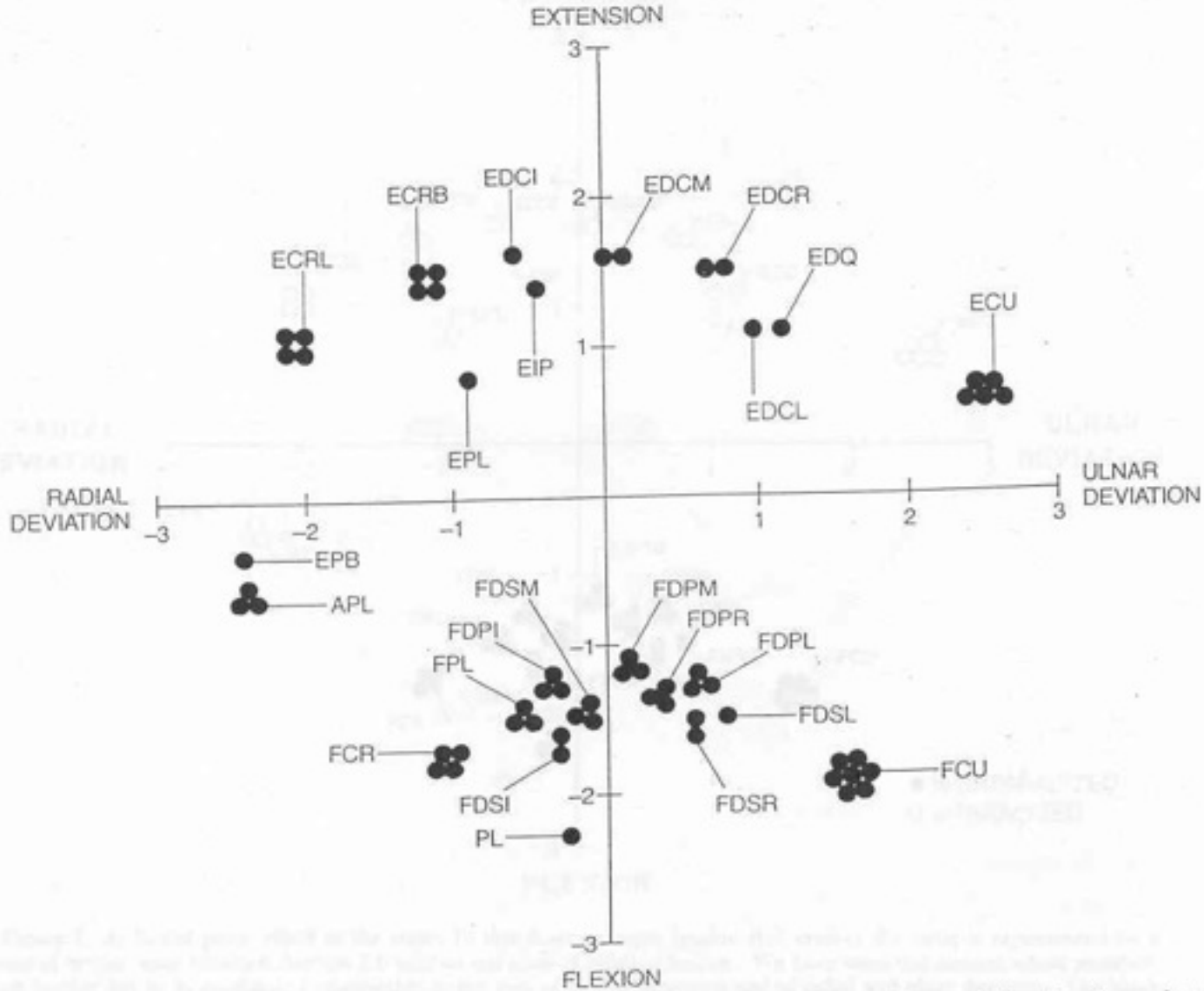
EXTENSION
3
2
1
–1
–2
–3
FLEXION
RADIAL DEVIATION
ULNAR DEVIATION
–3
–2
–1
1
2
3
ECRB
EDCI
EDCM
EDCR
ECRL
EDQ
ECU
EIP
EDCL
EPL
EPB
APL
FDSM
FDPM
FDPR
FDPI
FDPL
FPL
FDSL
FCR
FCU
FDSI
FDSR
PL

Planning

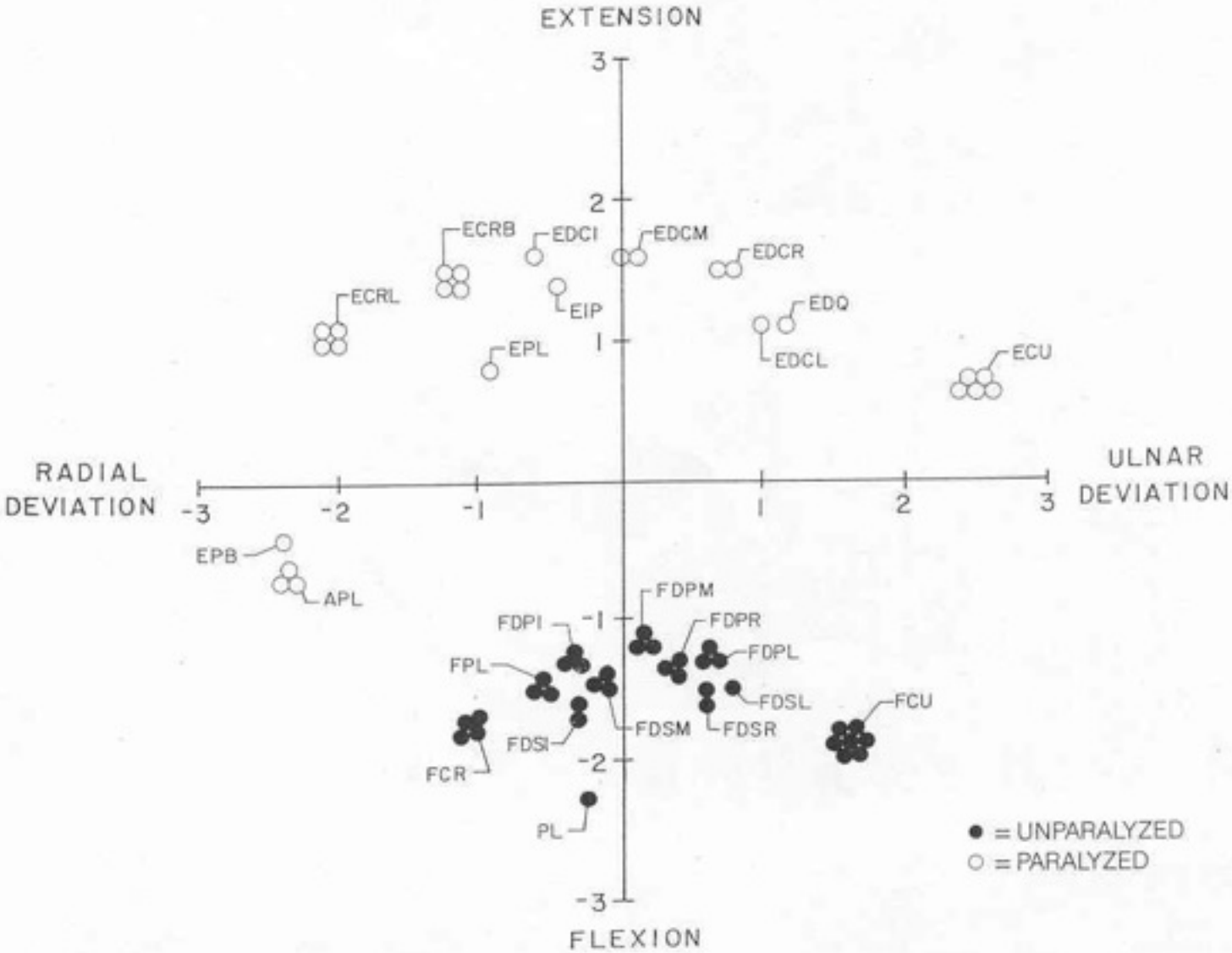
EXTENSION
FLEXION
RADIAL DEVIATION
ULNAR DEVIATION
3
2
1
-1
-2
-3
ECRB
EDCI
EDCM
EDCR
ECRL
EIP
EDQ
EPL
EDCL
ECU
EPB
APL
FDPM
FDPI
FDPR
FPL
FDPL
FDSL
FCU
FDSM
FDSR
FDSI
FCR
PL
● = UNPARALYZED
○ = PARALYZED

Planning

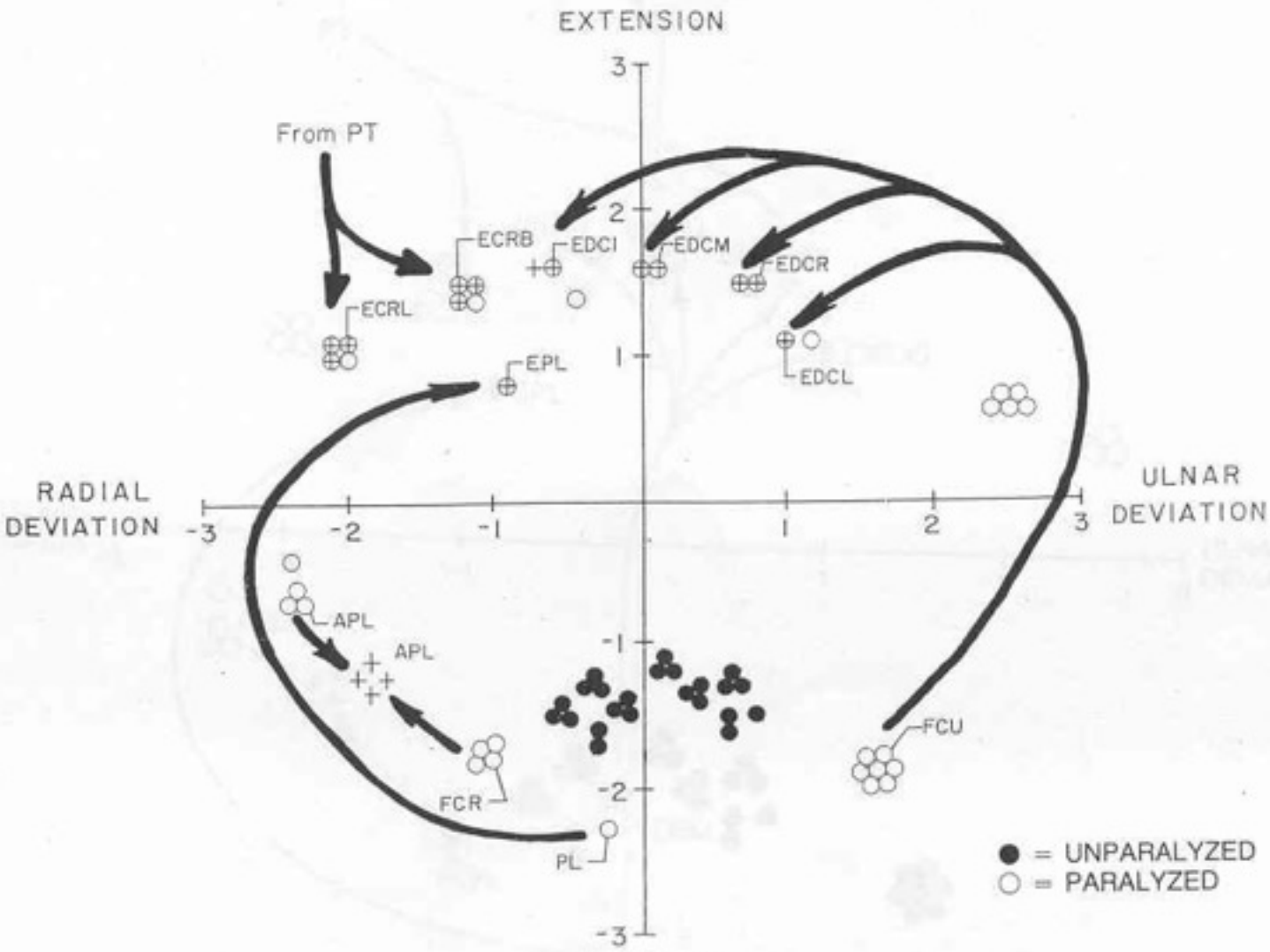
EXTENSION
FLEXION
RADIAL DEVIATION
ULNAR DEVIATION
From PT
ECRB
ECRL
EDCI
EDCM
EDCR
EDCL
EPL
APL
APL
FCR
PL
FCU
● = UNPARALYZED
○ = PARALYZED

Planning

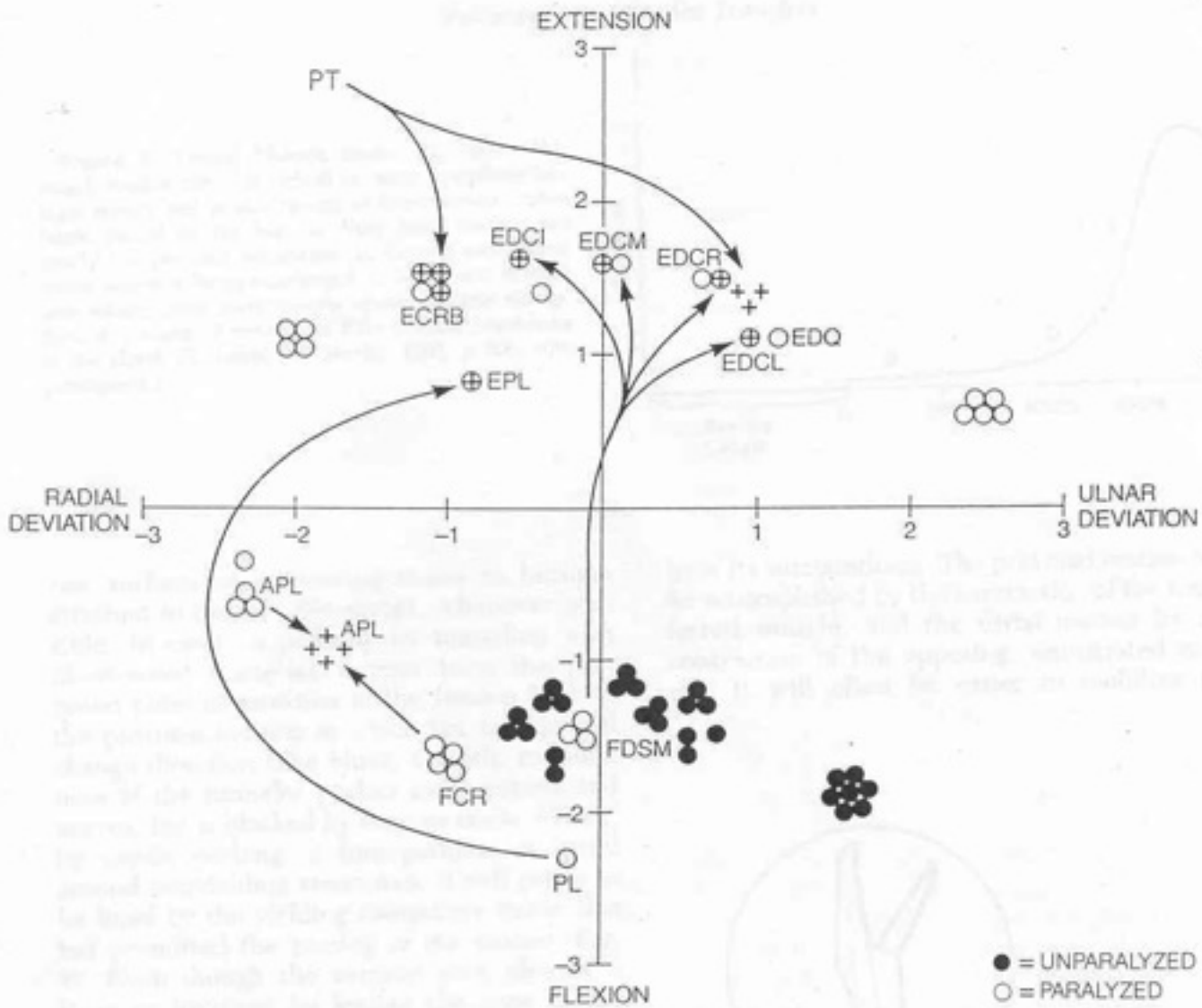
EXTENSION
3
2
1
-1
-2
-3
FLEXION
RADIAL DEVIATION
-3
-2
-1
1
2
3
ULNAR DEVIATION
PT
EDCI
EDCM
EDCR
ECRB
EDQ
EDCL
EPL
APL
APL
FCR
FDSM
PL
● = UNPARALYZED
○ = PARALYZED

Change in Muscle Following Transfer

- Myth:

  Muscle strength is decreased following transfer

- Maximum tension capability
  - Based on cross-sectional area of all fibers
  - Not changed by transfer

Change in Muscle Following Transfer

- What may change is range of excursion
  - Affected by adhesions
  - Scarring leads to resistance

Resistance

- Only when tendons pass around curves do they acquire synovial sheath
- Elsewhere, surrounded by connective tissue attached to nonmoving tissues by scar
- Nature of nonmoving tissues greatly affects results
  - Bone, fascia → poor result
  - Subcutaneous fat → better result

Resistance

- Scar adhesion is the most common cause of failure of tendon transfers
  - Use only blunt instruments to tunnel
  - Avoid “raw” surfaces
  - When scar forms to compliant tissue, still get excursion

Too Many Joints, Too Few Muscles

- In severe paralysis, don’t be too ambitious
- Trying to restore motion to all joints results in weakness an secondary deformity
- Better to achieve a few well supported actions
- Tailor to patient’s needs
- Consider joint fusion to provide stability

Remember

- When one muscle is used as a motor:
  - All insertions move together every time one of them moves
  - All insertions move the same distance
    - Example: PT to ECRB and ECU
      - ECRB must move twice as far for given wrist motion as ECU (twice the moment arm)
      - ECRB will become slack as soon as wrist extension intiated (held back by ECU)
      - Wrist will always ulnar deviate with extension

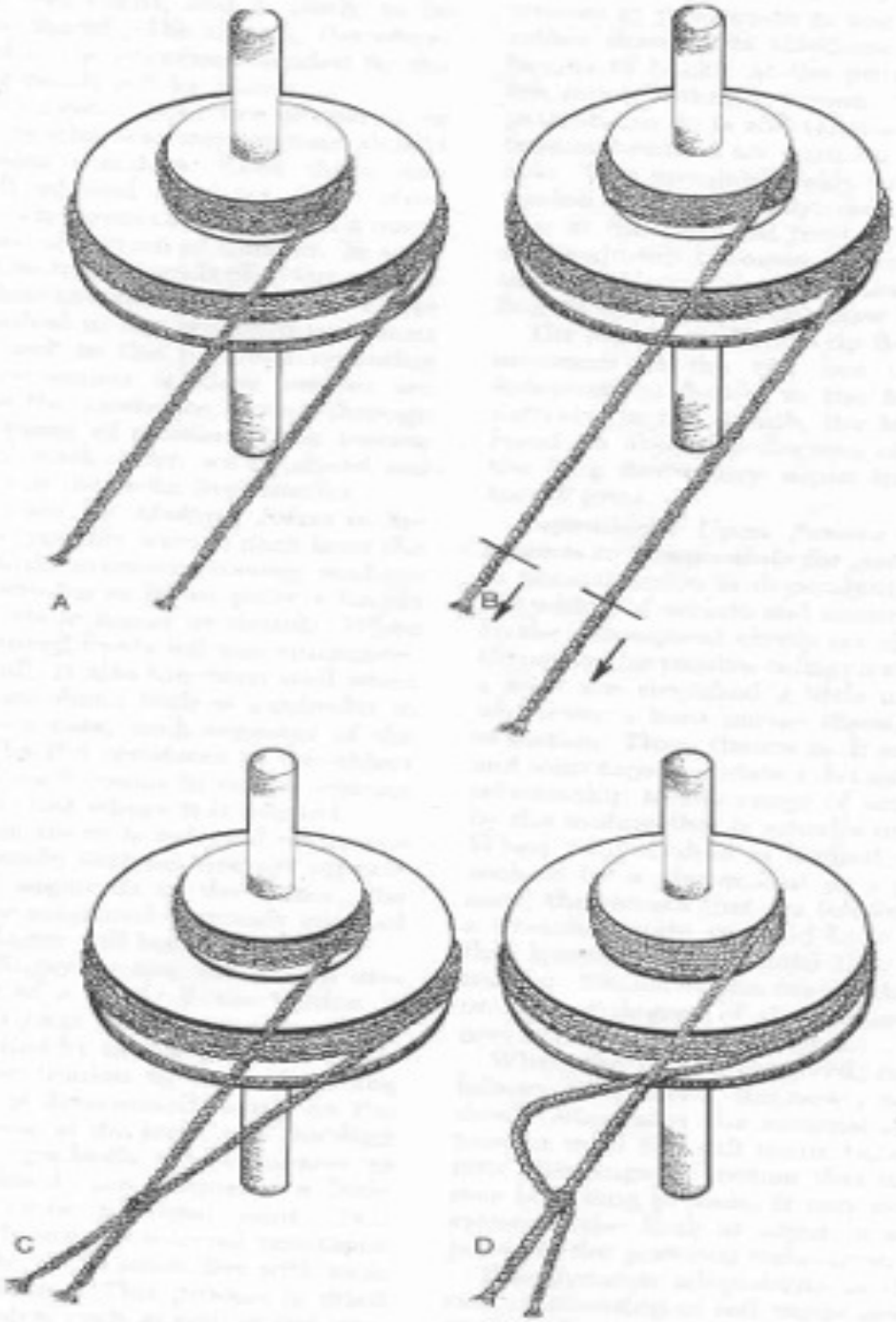
A
B
C
D

General Principles of Tendon Transfer

- Restore sensibility first
  - Primary nerve repair
  - Nerve grafting
  - Ensure recovery in progress prior to initiating reconstruction by tendon transfer
- Gain tissue equilibrium in the extremity
  - Edema
  - Scar
  - Joint stiffness

Principles of Tendon Transfer for Combined Nerve Injuries

- Individualize, don't "cookbook"
- Carefully plan multiple operations
- Combine multiple transfers so that postoperative rehabilitation can be unified by a single treatment goal
  - Transfer muscles with reasonably similar pre- and post-transfer function

Principles of Tendon Transfer for Combined Nerve Injuries

- Avoid crossing tendons if possible
- If must cross, consider Hunter rod at time of initial transfer with crossing tendon transfer done through newly created sheath at later stage

(Eversmann, 1988)

Principles of Tendon Transfer for Combined Nerve Injuries

- Do not use functional muscles to stabilize while awaiting reinnervation
  - i.e. do not use “internal splints”
  - Fewer muscle-tendon units available
- Avoid use of reinnervated muscle for tendon transfer
- Avoid spastic muscle

Principles of Tendon Transfer for Combined Nerve Injuries

- In general, results from tendon transfers for multiple nerve injuries are not as good as those for single nerve injuries
- Goal of reconstruction is a good helper hand

Dynamic Tenodesis

- Excursion of a tendon transfer can be augmented if that transfer crosses the wrist and can be enhanced by wrist motion

Low (Distal) Median-Ulnar Nerve Palsy

- Most common combined nerve injury in upper extremity
- Complete intrinsic muscle paralysis
  - Claw hand deformity
- Volar sensory loss all digits

Low (Distal) Median-Ulnar Nerve Palsy

- Flat transverse palmar arch
- MP hyperextension
- PIP hyperflexion
- Adduction contracture first web
- Patient flexes wrist to get finger extension (functional tenodesis) may result in flexion contracture of wrist

(J Hand Surg, 1983)

Low (Distal) Median-Ulnar Nerve Palsy

- Basic requirements
  - Key pinch
    - Strong thumb adductor
  - Thumb abduction/opposition
  - Tip pinch between thumb and index
  - PIP power flexion
  - Coordination of MP and IP motion
  - Sensibility for key or tip pinch
    - Repair median nerve

Low (Distal) Median-Ulnar Nerve Palsy

- Radial-innervated muscles available for transfer
  - ECRB
  - ECRL
  - BR
  - EIP
  - EDM
    - Only if EDC to small is present
  - APL
- FDS may also be available for transfer, but tendons often lacerated with initial injury
  - Repair tendons first, then harvest later for transfer

Low (Distal) Median-Ulnar Nerve Palsy

- Restore sensation first
- Splinting to avoid
  - Adduction contracture of thumb
  - PIP flexion contracture of fingers
- All transfers for low median-ulnar nerve palsy can be done at one time

Low (Distal) Median-Ulnar Nerve Palsy

Table 50–1. COMBINED LOW (DISTAL) MEDIAN AND ULNAR PALSY

Needed Function	Preferred Transfer	Alternative Transfer
Thumb adduction—key pinch	ECRB with free tendon graft between 3rd and 4th metacarpals to abductor tubercle of thumb (APB tendon)[61,72,86,87]	FDS (long) to abductor tubercle of the thumb with palmar fascia and flexor tendons as pulleys[5,36,44,83,89]
Thumb abduction—opposition[16,23,25,64]	EIP around pisiform pulley through thenar muscle tunnel to APB tendon insertion[19,48,59] and EPL tendon[79]	PL to APB tendon insertion[12] *or* FDS (ring) to APB tendon[78]
Thumb-index tip pinch	APL slip with free tendon graft to 1st dorsal interosseous tendon[49] and arthrodesis of thumb MP joint[59,77]	EPB[15,27] or PL[38] to 1st dorsal interosseous tendon (if thumb MP joint has been arthrodesed)
Metacarpal (palmar) transverse arch and adduction for little finger	EDM tendon split and ulnar half passed volar to deep transverse metacarpal ligament to radial collateral ligament of MP joint of little finger or A2 pulley of flexor sheath[2,54,59]	FDS (little) to deep transverse metacarpal ligament between 4th and 5th metacarpals *or* FDS (long or ring) combined as single transfer for thumb adduction and metacarpal arch[5,54,59]
Power flexion for proximal phalanges and integration of MP and IP motion (clawed fingers)	ECRL or BR to all 4 fingers using 4-tailed free tendon graft and flexor sheath insertion (A2 pulley)[6,7,13,20,76,100] or lateral bands of dorsal apparatus	FCR (if wrist flexion contracture) with 4-tailed free tendon graft to either flexor sheath (A2 pulley) or dorsal apparatus[79,80,83]
Radial and ulnar volar sensibility	Superficial radial nerve translocation[43,92] or cutaneous neurovascular island[26]	Cross-finger index-to-thumb fillet flap[24,31,57] (superficial radial nerve)

Low (Distal) Median-Ulnar Nerve Palsy

- Tailor reconstruction to patient needs
- Emphasis on strength of *grasp*, *pinch* <u>or</u> effective *finger position* (more intrinsic plus)

Main Functional Loss - Grasp

- Easy fatiguability
- Difficulty opening jars
- Most effective transfer
  - ECRL transfer using 4-tailed free tendon graft
  - Pass grafts volar to transverse metacarpal lig
  - Insert into flexor sheath (A2 pulley) or radial side of proximal phalanx (bone insertion)
  - Provides power grip
  - With wrist flexion, no extension at MP
  - If undesirable, FDS to A1 pulley (Zancolli Lasso)

(J Bone Joint Surg, 1973)

Main Functional Loss - Pinch

- Difficulty pushing buttons
- Difficulty turning keys, opening soda cans
- Need two intrinsic transfers to regain control of thumb
  - Often a third to restore adduction, opposition and short flexor function

Main Functional Loss - Pinch

- Adductor transfer
  - FDS (ring) to adductor insertion base of thumb proximal phalanx
  - Passed deep to flexor tendons
  - If FDS (ring) not available:
    - FDS (middle)
    - ECU with tendon graft
    - BR with tendon graft passed between index and middle metacarpals
    - ECRB with tendon graft passed between middle and ring metacarpals inserted on APB tendon

Main Functional Loss - Pinch

- Opposition
  - EIP
  - Rerouted around ulnar border of hand (pisiform pulley), across thenar eminence, inserted on APB, or looped around thumb extensors
  - So effective, hard to recommend alternative
    - FDS (ring) to APB
    - PL to APB

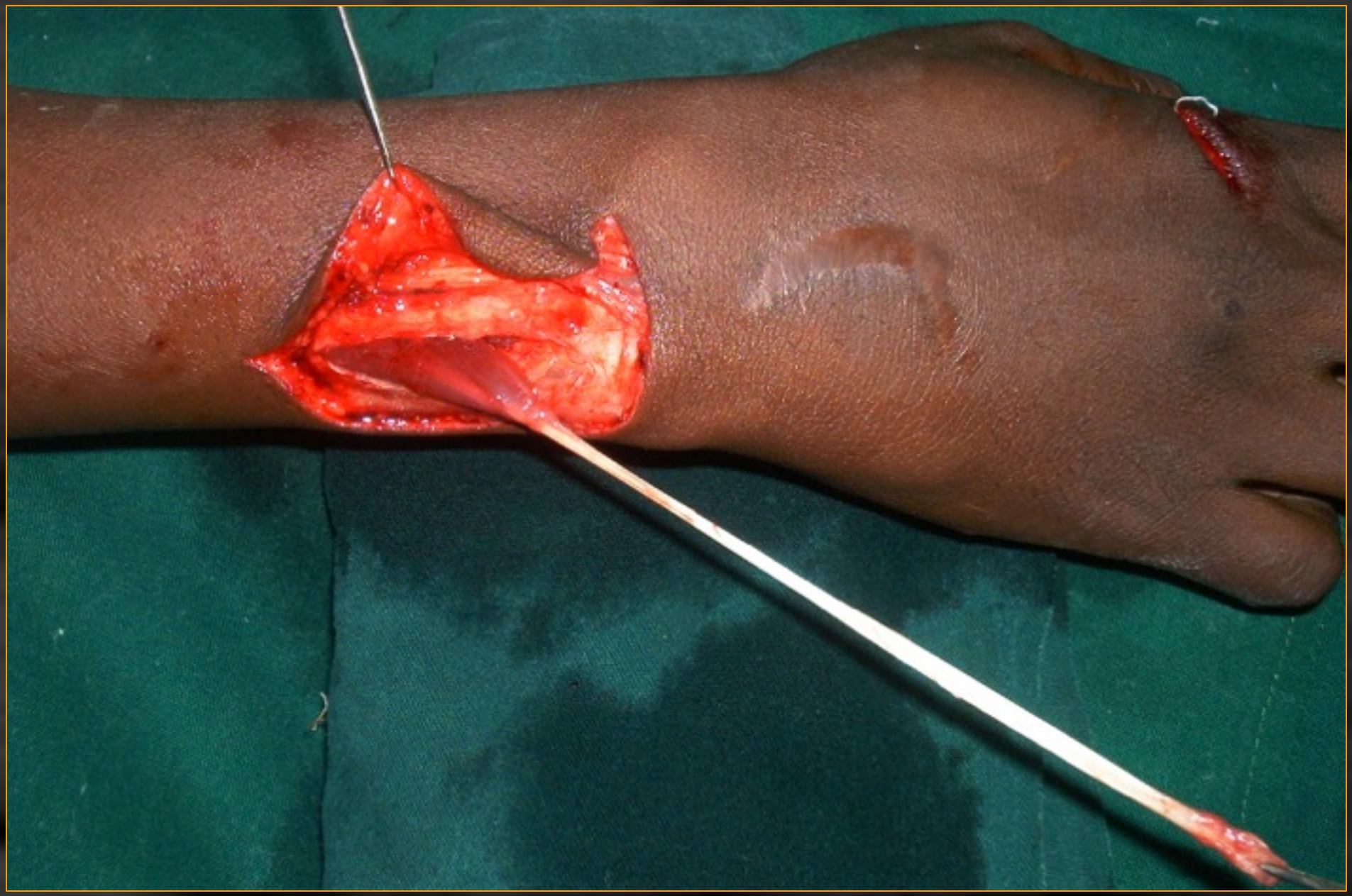

5 days post-op abduction & opposition

4 week post-op abduction & opposition

Main Functional Loss - Pinch

- Thumb MP fusion
  - Negates need for short flexor in intrinsically deprived thumb
  - Provides stability for adductor and opponens transfers, which can be dampened by thumb MP flexion

Main Functional Loss - Pinch

- Radial stability to index finger
  - If ECRL 4-tailed graft insufficient
  - BR extended with tendon graft to radial side of index finger

(Plast Reconstr Surg, 1984)

High (Proximal) Median-Ulnar Nerve Palsy

"The hand will rarely be used for precision activities following this severe injury, even if minimal muscle balance is resored."

Green's Operative Hand Surgery
Fourth Edition

High (Proximal) Median-Ulnar Nerve Palsy

- Goals of reconstruction:
  - Helper hand
  - Simple grasp
  - Some ability to pinch
    - Mostly key pinch
- Utilize dynamic tenodesis
  - Requires full wrist range of motion

High (Proximal) Median-Ulnar Nerve Palsy

Table 50–2. COMBINED HIGH (PROXIMAL) MEDIAN AND ULNAR PALSY

Needed Function	Preferred Transfer	Alternative Transfer
Thumb adduction—key pinch (AP)	ECRB with free tendon graft between 3rd and 4th metacarpals to abductor tubercle of thumb[61,86,87]	BR or EIP with free tendon graft between 3rd and 4th metacarpals[14] to abductor tubercle of thumb (APB tendon)[61]
Thumb flexion (IP joint)	BR to FPL in forearm[51,53,70]	Tenodesis of FPL distal to MP joint of thumb
Thumb abduction—opposition (APB)	EIP around pisiform pulley[19,48,59,87] to insertion of APB *plus* EPL tendons[81,82]	EPL[78] or ECU[36,41] with graft around pisiform pulley to APB tendon (thumb MP joint is fused and no active motion at IP joint)
Thumb-index (or long) pinch (tip pinch)	Arthrodesis of thumb MP joint *and* APL slip with free tendon graft to 1st dorsal interosseous tendon[49,58,62]	EPB[15,27] or PL[38] to dorsal interosseous tendon *and* fusion of thumb MP joint[77]
Finger flexion (FDP)	ECRL to all 4 tendons of FDP[51,53] with possible tenodesis of distal IP of ulnar 3 fingers[8,51]	Biceps brachii extended with FCR tendon to tendons of FDP[32]
Clawed fingers—power for flexion of proximal phalanx *and* integration of MP and interphalangeal motion	Tenodesis of all 4 digits with free tendon graft from dorsal carpal ligament volar to deep transverse metacarpal ligament to lateral bands of extensor apparatus[80,81] or from deep transverse metacarpal ligament to extensor apparatus[75]	Capsulodesis of MP volar capsule[97,100] *or* Arthrodesis of PIP joints[32,77] *or* Arthrodesis of MP joints[35]
Metacarpal (palmar) arch and adduction for little finger	EDM to deep transverse metacarpal ligament[2] (EDC of little finger must be active)	EDM to radial lateral bands (extensor hood) of ring and little fingers (Fowler-Bunnell)[88]
Wrist flexion		ECU to insertion of FCU
Radial and ulnar volar sensibility	Superficial radial-innervated index fillet flap to palm[55,58,59] *or* First dorsal metacarpal artery neurovascular island[39,69,85]	Superficial radial nerve translocation *or* Free vascularized nerve graft[93]

High (Proximal) Median-Ulnar Nerve Palsy

- Finger flexion
  - ECRL to FDP
    - Anastomose tendons of FDP together before inserting ECRL
    - Resting cascade with index slightly more extended than middle and so on
    - Transfer proximal to carpal tunnel in distal 1/3 of forearm with ECRL rerouted around radial side of forearm

ECRL to FDP

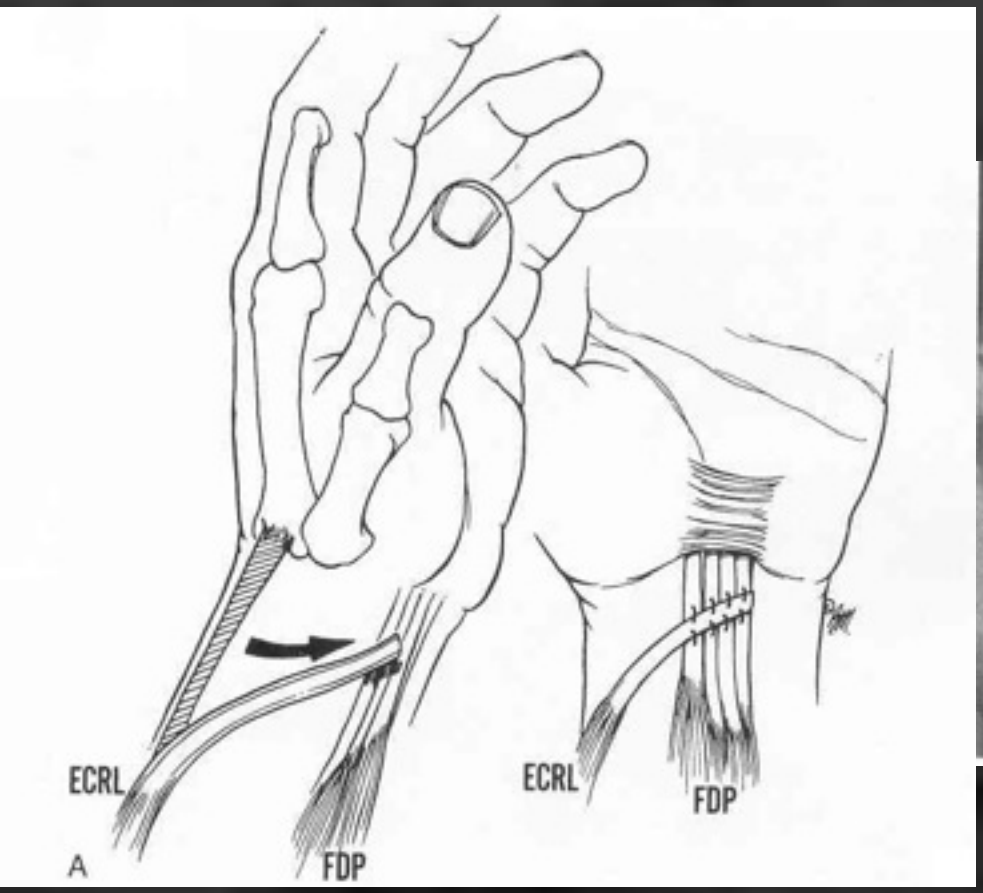

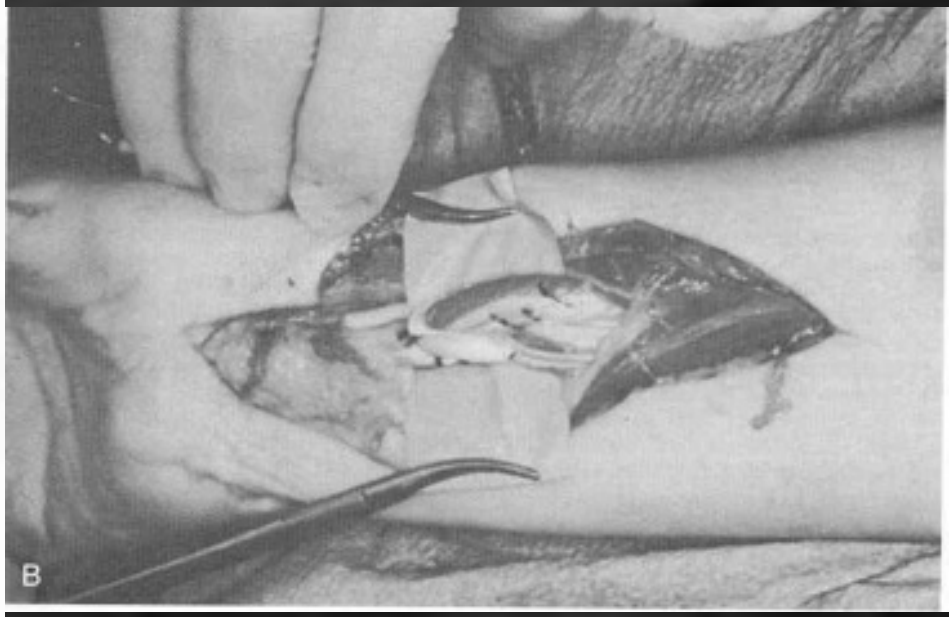

High (Proximal) Median-Ulnar Nerve Palsy

- Thumb flexion
  - BR to FPL
    - Disadvantage: crosses multiple joints
    - Can fixate to bone distal to elbow joint to eliminate mechanical disadvantage
    - Set tension to again take advantage of tenodesis effect of wrist extension
    - Arthrodesis of thumb MP strengthens both tip and key pinch

High (Proximal) Median-Ulnar Nerve Palsy

- Wrist flexion
  - ECU to FCU
    - To provide some wrist flexion
    - ECU excursion 1/3 that of FCU normally
    - Do not compromise wrist extension needed for dynamic tenodesis

High (Proximal) Median-Ulnar Nerve Palsy

- Opposition
  - EIP around pisiform pulley to APB and EPL insertions (Riordan's insertion)

    (Bull Hosp Jt Dis, 1984)
  - Pass through tunnel in denervated thenar muscles to prevent bowstringing

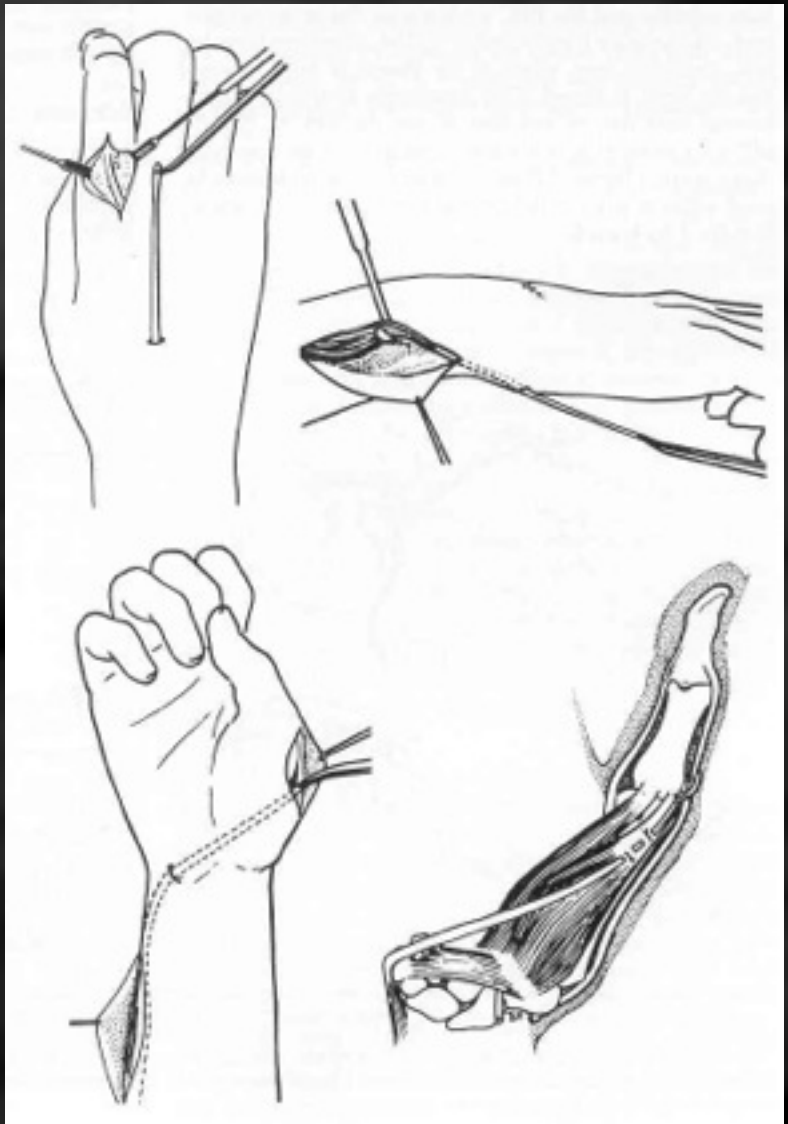

High (Proximal) Median-Ulnar Nerve Palsy

- Zancolli's capsulodesis
  - Static procedure for control of finger position
  - Holds MP in flexion during IP flexion and extension

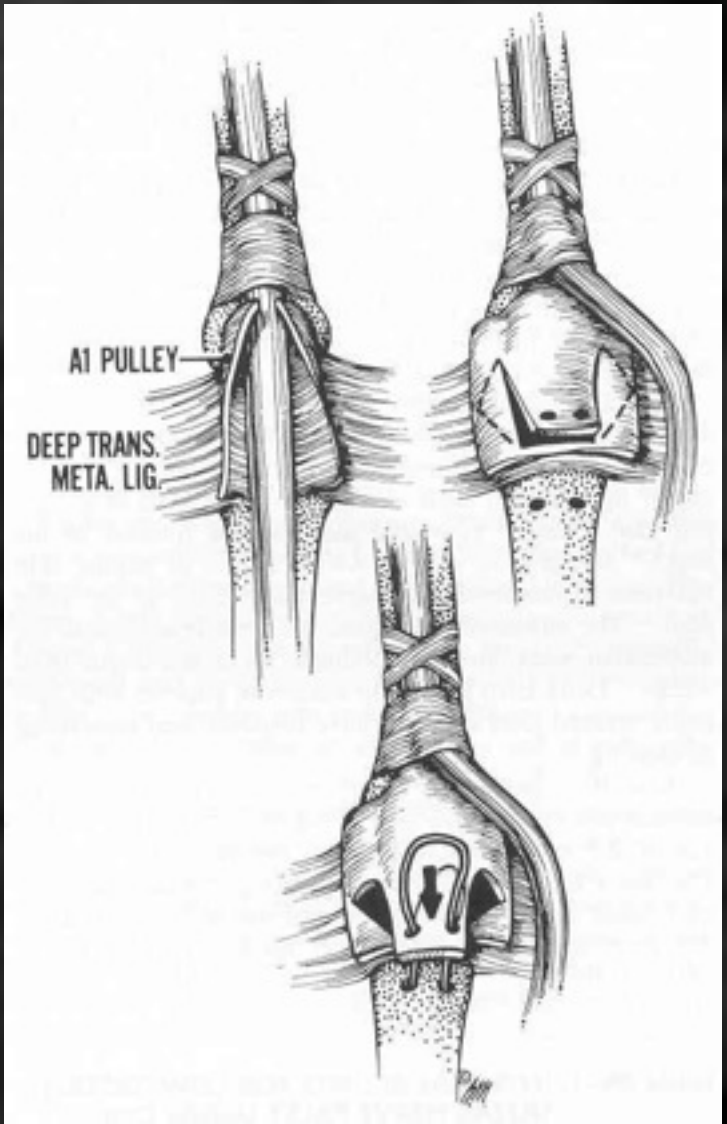

High (Proximal) Median-Ulnar Nerve Palsy

- Sensibility
  - Fillet flap, index finger
    - Superficial radial branch brings protective sensation to first web space
      (J Bone Joint Surg, 1969)
  - Neurovascular island flap
    - FDMA + superficial radial nerve
    - Can provide protective sensation to thumb pulp

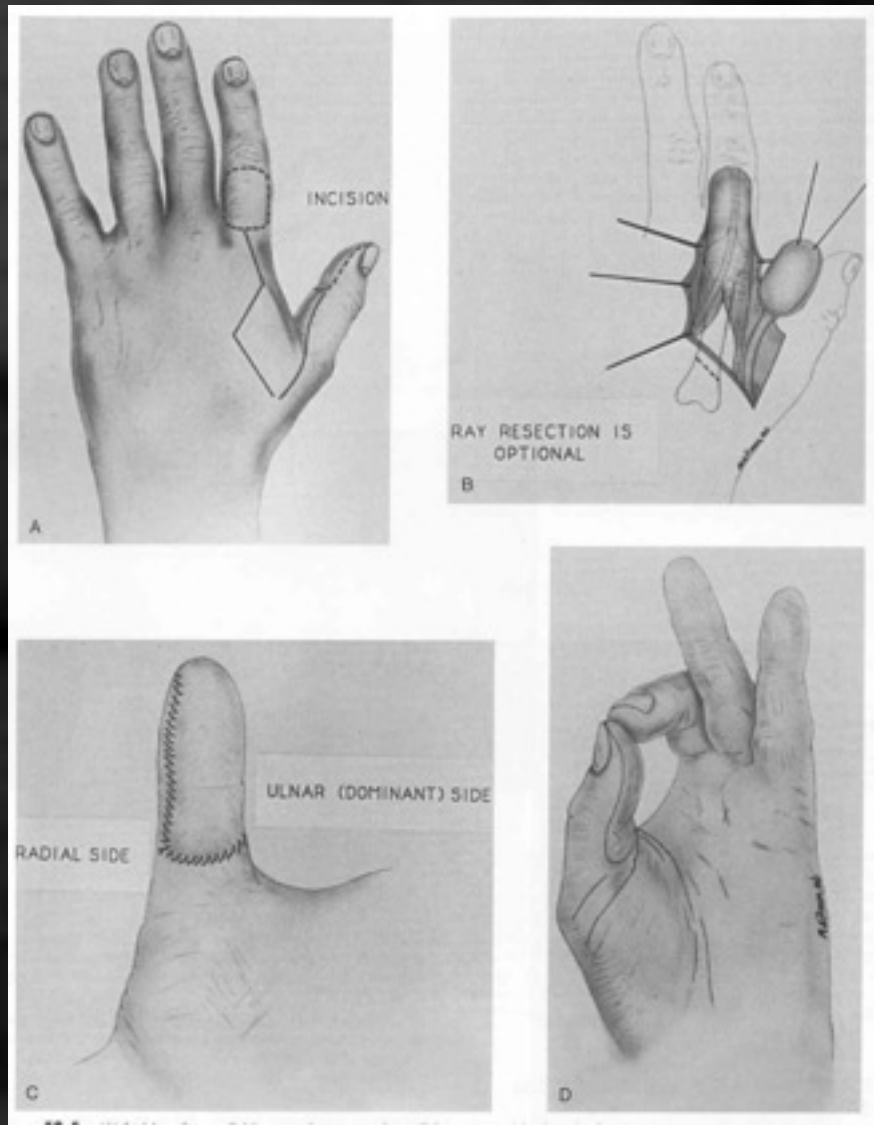

High (Proximal) Ulnar-Radial Nerve Palsy

- Retain radio-volar sensibility
- Few available muscle-tendon units to reconstruct functional deficit
- Staged reconstruction
- Difficult rehab
  - Restore both finger flexion and extension
  - Restore both thumb adduction and abduction

High (Proximal) Ulnar-Radial Nerve Palsy

Table 50–3. COMBINED HIGH (PROXIMAL) ULNAR AND RADIAL PALSY

Needed Function	Preferred Transfer	Alternative Transfer
Wrist extension	PT to ECRB[9]	
Thumb adduction—key pinch	Half of FDS (long) as split transfer to abductor tubercle of thumb[52,55,59] *and*	
Clawed fingers—Metacarpal (palmar transverse arch) *and* Power flexion of proximal phalanx *and* Integration of MP and IP motion	Half of FDS (long) in 2 slips to A2 pulley of flexor sheath for ring and little fingers[13,52,55,59,100] *and—later* Arthrodesis of proximal IP joints and ring and little fingers if unable to fully extend[51,53,55]	Tenodesis with free tendon graft from radial lateral band of dorsal apparatus to deep transverse metacarpal ligament[73] *or* Capsulodesis of MP volar capsule[59,97,100]
Thumb-index tip pinch	Arthrodesis of thumb MP joint[51,53,55,77]	
Proximal thumb stability for abduction and wrist flexion (radial aspect)	Tenodesis of APL to radius[55,59,61,72]	FCR (yoke insertion) to APL and EPB[55,59,61,72]
Wrist flexion (ulnar aspect)		PL to insertion of FCU[64,72]
Finger and thumb extension	FDS (index and ring) through interosseous membrane to EDC and EPL[4]	PL to EDC and EPL[80]
Finger flexion (ring and little)	Tenodesis of FDP (long) as active motor to ring and little FDP[8,96] with double suture line *and* Tenodesis of DIP joint of ring and little fingers using FDP tendons[53,69]	
Volar sensibility—ring and little fingers	Median digital nerve translocation[43,92]	Free vascularized nerve grafts[93] *or* Neurovascular cutaneous island pedicle[26]

High (Proximal) Ulnar-Radial Nerve Palsy

- Wrist extension
  - PT to ECRL/ECRB
    - First described by Jones in 1917

      (Notes on Military Orthopedics, 1917)
    - Problem:
      - With loss of FCU (sparing FCR) get significant radial imbalance at wrist
    - Solutions:
      - ECRB only insertion
        - » More motion
      - Yoke insertion to ECRL and ECRB
        - » Less radial deviation

PT to ECRB

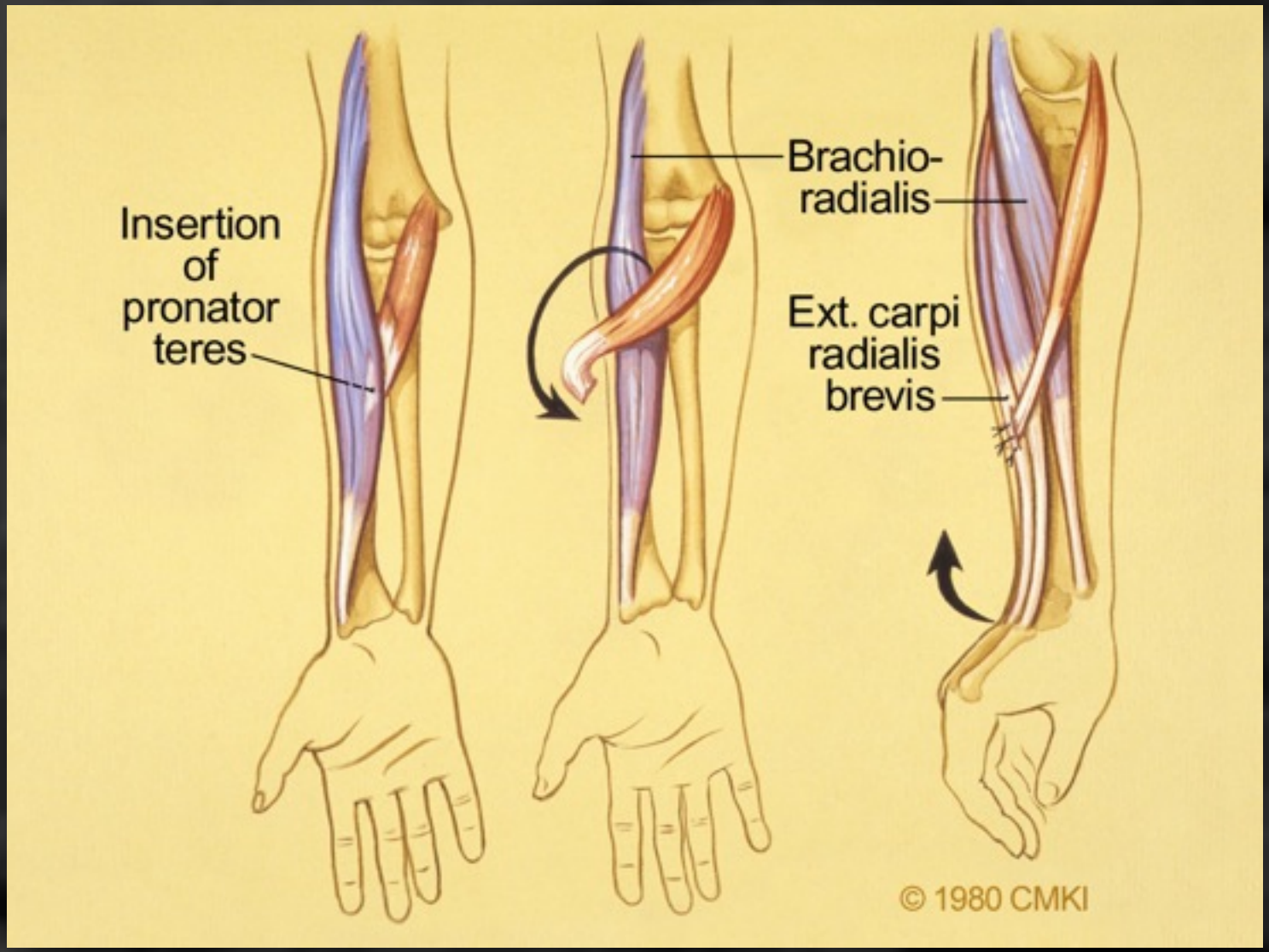
Insertion of pronator teres
Brachio-radialis
Ext. carpi radialis brevis
© 1980 CMKI

Yoke

- Definition:

  "1. (n) a wooden frame or bar with loops or bows at either end, fitted around the necks of a pair of oxen, etc. for harnessing them together…

  2. (v) to join together, link."

  Webster's New World Dictionary, Second Edition

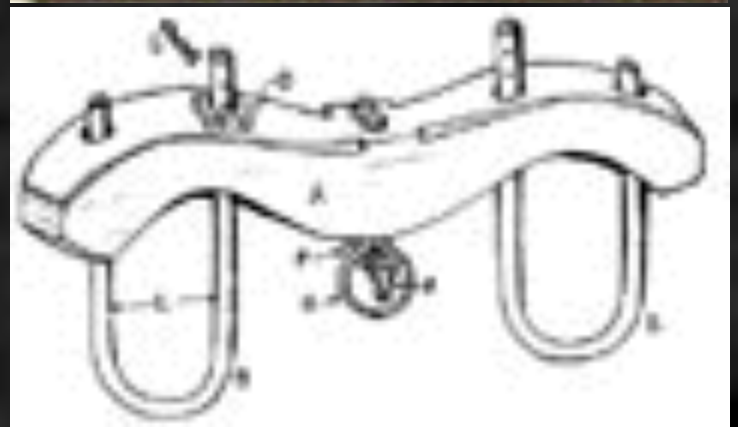

Yoke Insertion

- Detach ECU at musculotendinous junction
- Resuture ECU at slightly greater tension than ECRL to PT transfer
- More balanced dorsiflexion position than simple transfer to ECRB
- Less motion than PT to ECRB transfer

(Hand Surgery, 2nd Ed., 1975)

Yoke Insertion

- If injury to ulnar nerve is distal to branch to FCU, yoke insertion of PT is not necessary

(Orthop Clin North Am, 1974)

High (Proximal) Ulnar-Radial Nerve Palsy

- Finger and thumb extension
  - FDS (index,middle) to EDC through interosseous membrane
    - Must excise 9cm of interosseous membrane
    - Avoid anterior interosseous nerve and artery
  - EDC (middle) anastomosed to EPL
  - Can use PL for transfer to EPL and APL if present
- Thumb adduction
  - FDS (ring) to adductor pollicis
  - Thumb MP arthrodesis

High (Proximal) Ulnar-Radial Nerve Palsy

- Finger flexion
  - Side-to-side anastomosis of FDP ring and small to FDP middle
  - Leave FDP index to have some independent motion

High (Proximal) Median-Radial Nerve Palsy

- Vast loss of strength and stability of fingers and thumb
- Sensibility only ulnar ½ ring and small fingers
- Reconstruction results in only marginally functional hand only slightly better than prosthesis

High (Proximal) Median-Radial Nerve Palsy

- Must attempt to restore continuity of median nerve
- All wrist motors lost except FCU
- Wrist stability can only be gained by arthrodesis at expense of motion
- Finger flexion not enhanced by wrist extension, so total ROM limited
- Wrist arthrodesis provides FCU for use as tendon transfer

High (Proximal) Median-Radial Nerve Palsy

Table 50–4. COMBINED HIGH (PROXIMAL) MEDIAN AND RADIAL PALSY

Needed Function	Preferred Transfer	Alternative Transfer
Forearm pronation	Biceps brachii tendon rerouting around radius[74,99]	
Wrist extension and flexion	Radiocarpal arthrodesis[33,90]	
Finger flexion	Tenodesis of FDP ring and little (active motors) to FDP index and long[96]	
Finger and thumb extension	FCU to tendons of EDC and EPL[51,53,62,80]	
Proximal thumb stability for abduction	Arthrodesis of thumb MP joint[52,56,62] *and* Tenodesis of APL tendon to radius[55]	
Thumb abduction (opposition)		ADQ to insertion of APB[45] *or* AP tendon insertion from adductor tubercle to abductor tubercle[25]
Thumb flexion	Tenodesis of FPL across thumb IP joint[58]	Biceps brachii extended with FCR tendon to tendon of FPL[32]
Radiovolar sensibility	Ulnar digital nerve translocation[43,92]	Neurovascular cutaneous island pedicle from ring finger[52,57,69] *or* Free vascularized nerve graft[93]

High (Proximal) Median-Radial Nerve Palsy

- FDP sutured side-to-side for ulnar-innervated mass action
  - Index and long under greater tension
  - Resting fingers in “straight” rather than “oblique” transverse line

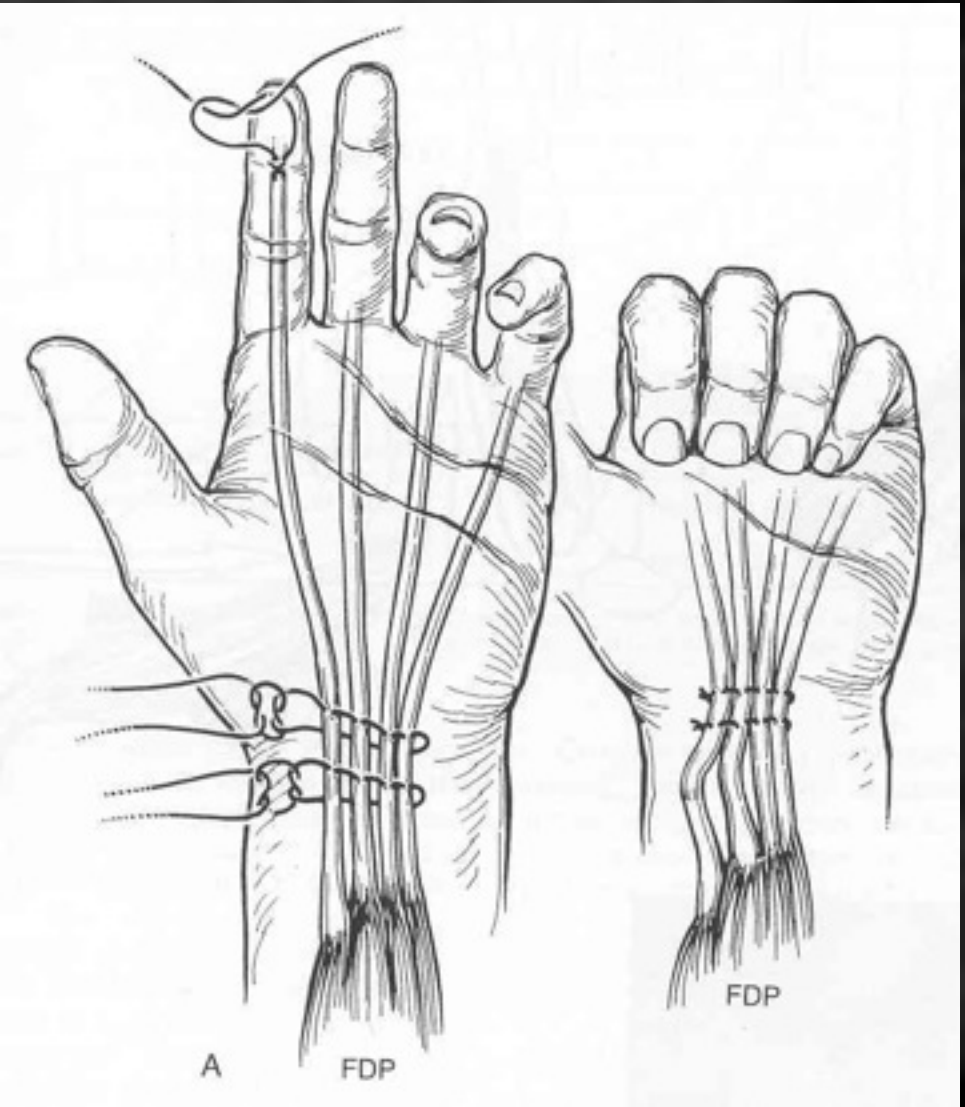

High (Proximal) Median-Radial Nerve Palsy

- Digital extension
  - FCU to EDC and EPL

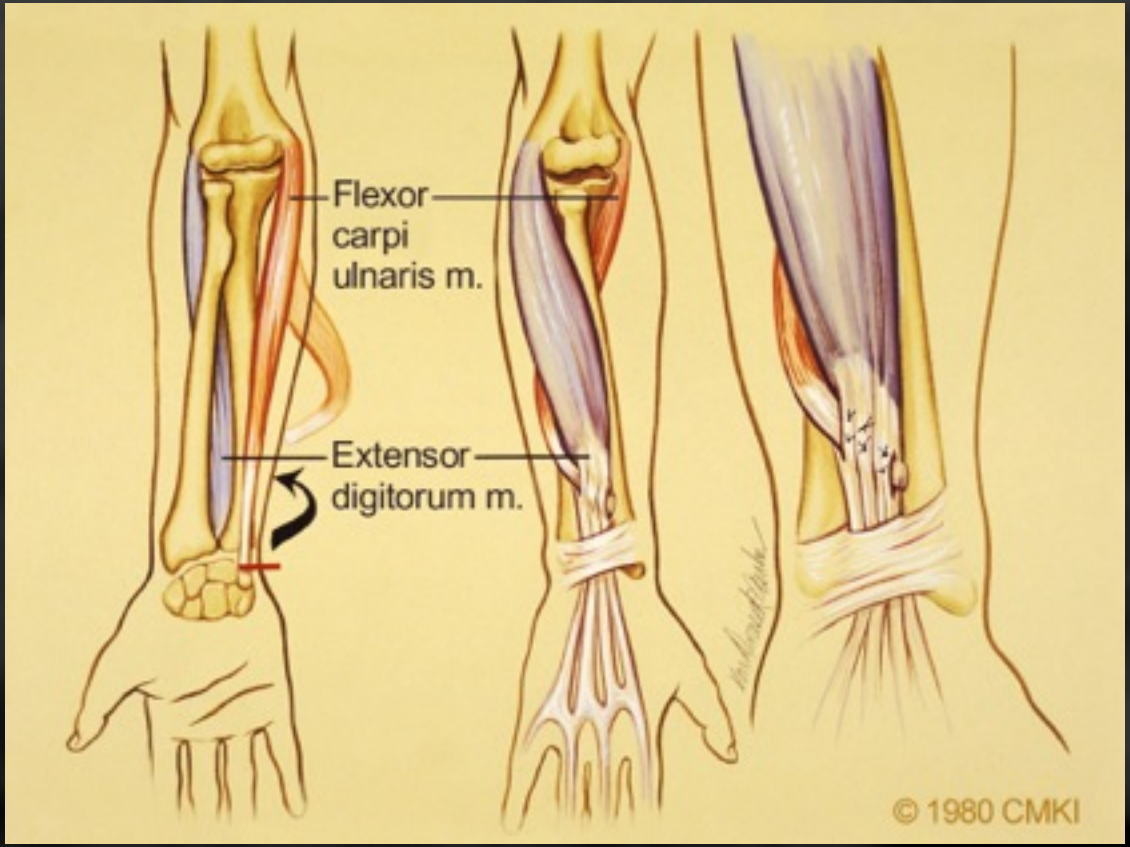

Summary

- Nearly all patients with combined nerve palsies will require multiple operations to restore function
- Procedures must be well thought out and carefully planned
- Must design reconstructive plan to meet patient's specific needs
- Goal is to redistribute assets that are available, not recreate a normal hand
- The more complex the surgical plan, the more likely it is to fail